

# EQUINE DISTAL LIMB

## Diagnostic Imaging Case Discussion

Alex Valdés, DACVR

Assistant Professor of Diagnostic  
Imaging

Colorado State University

College of Veterinary Medicine

# Ultrasonography

- Modality of choice for soft tissue evaluation in most cases
- No known hazard
- Experience is required
- Operator dependable
  - Most common source of erroneous interpretation and misdiagnosis

# Nuclear Scintigraphy

- Traces physiological processes
- Functional distribution of a  $^{99m}\text{Tc}$ -polyphosphonate in the body
- High affinity for the Ca-hydroxy-appetite molecule in bone
- High sensitivity      Low specificity
  - Early detection of abnormalities prior to anatomical changes
  - Poor anatomical architectural detail

# Indications For A Nuclear "Bone Scan"

- Ill defined, obscured/unblockable lameness
- Recheck of known lesion
- Spine conditions (facet DJD, impingement dorsal processes)
- Areas difficult to radiograph (lumbar, pelvic, sacro-iliac and hip joint)
- The radiographically normal painful joint
- Pre-purchase examinations
- Bone viability
- Miscellaneous
  - Disease of muscle, vascular abnormalities

# Computed tomography

- Excellent imaging modality for bone evaluation
  - Multi-Planar Reconstruction and 3D
  - Surgical planning
- Soft tissue evaluation is best achieved with use of contrast material (iodinated)
  - Intra-arterial
  - Intra-articular

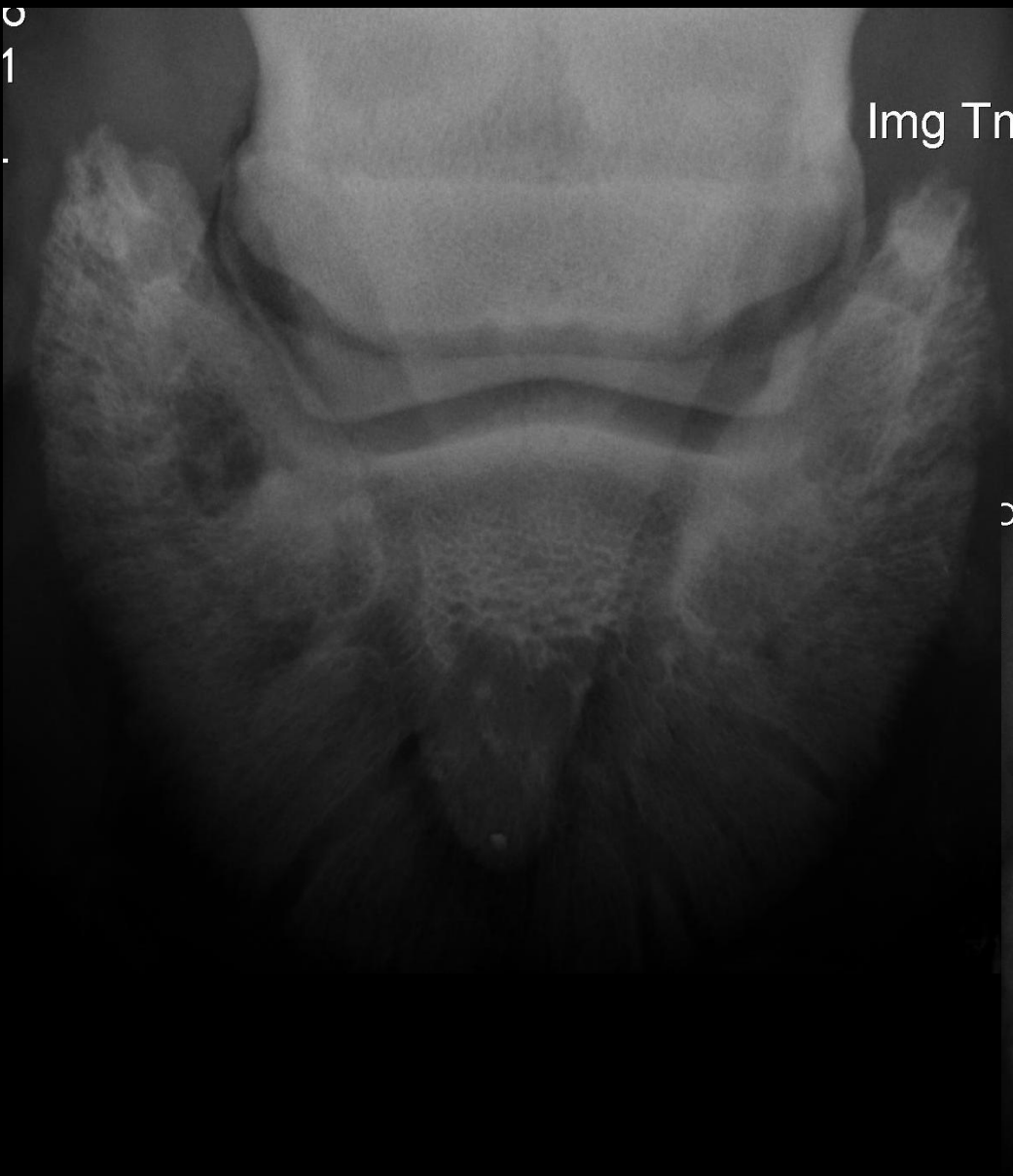# Magnetic Resonance

- Best modality for evaluation of the equine distal limb
- Excellent soft tissue and bone detail
- Differentiation of tissue composition based on hydrogen content
- Of all imaging modalities, MR is the one that allows visualization of the greater number of structures

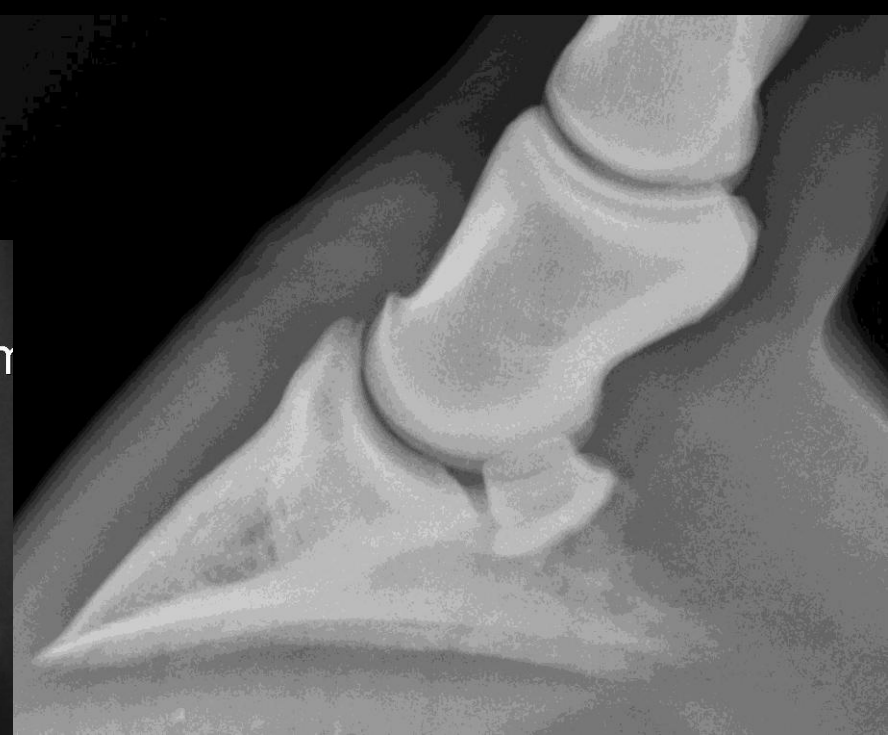# Case 1

- 7 yr-old WB gelding
- 3 day event
- 3/5 LF lameness for 4-6 weeks, positive to distal limb flexion
- Mild response to NSAID's
- Significant improvement to abaxial block

0  
1



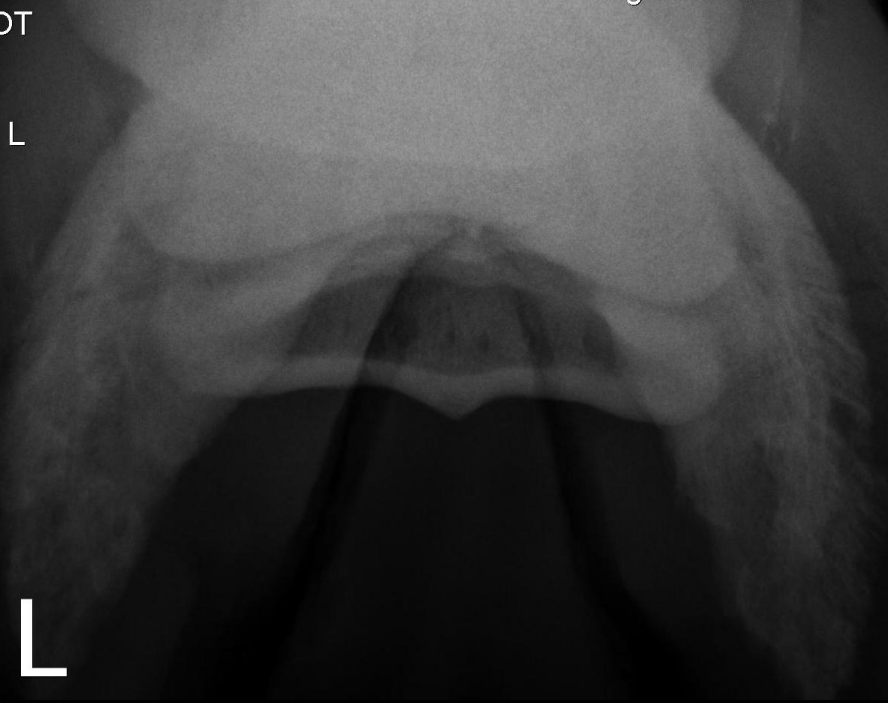
Img Tr

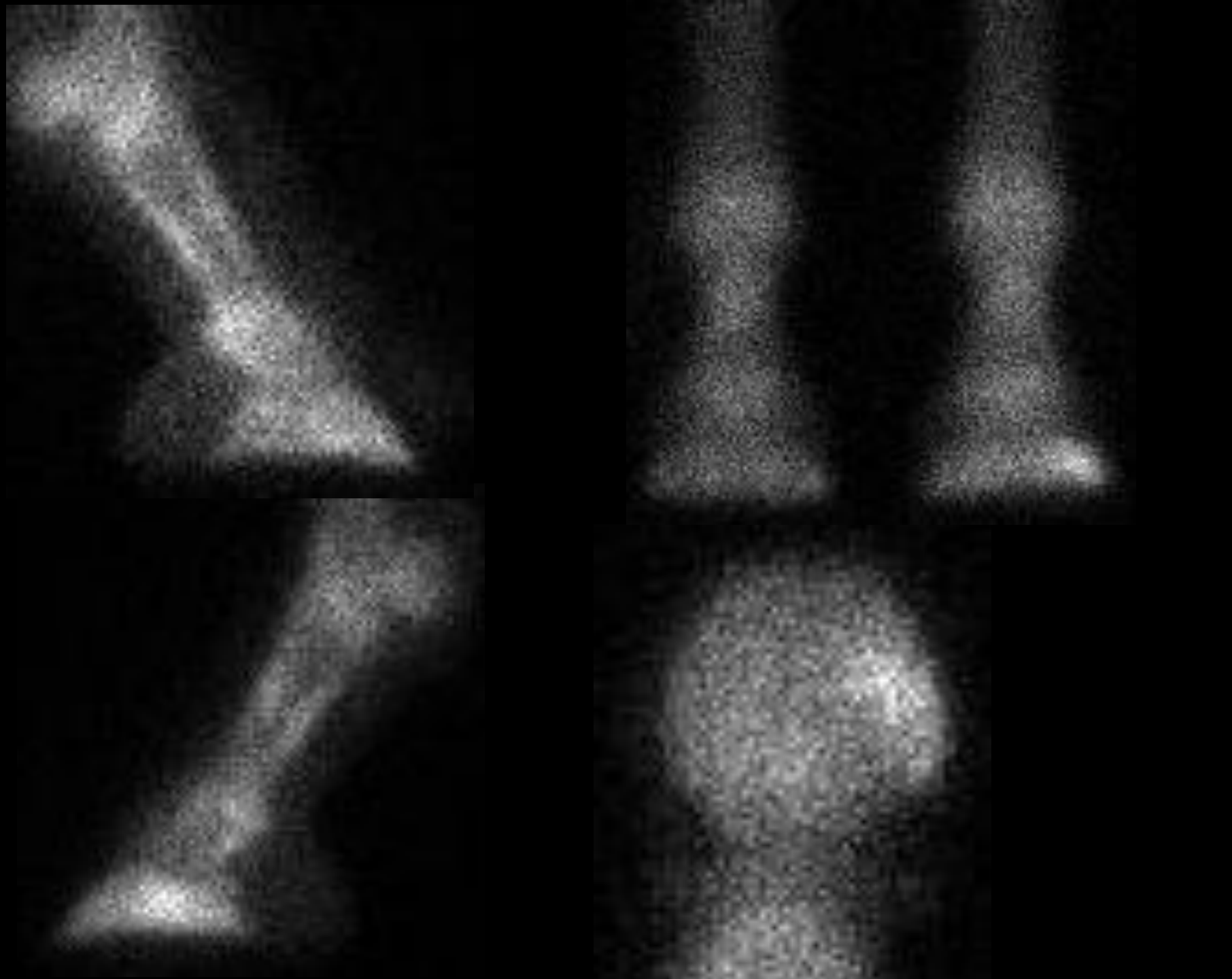


DT

L

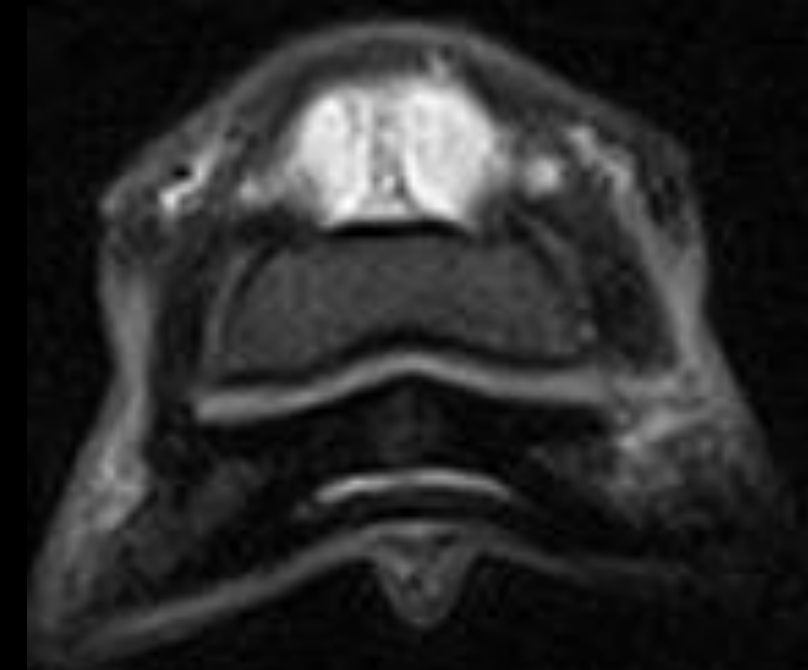
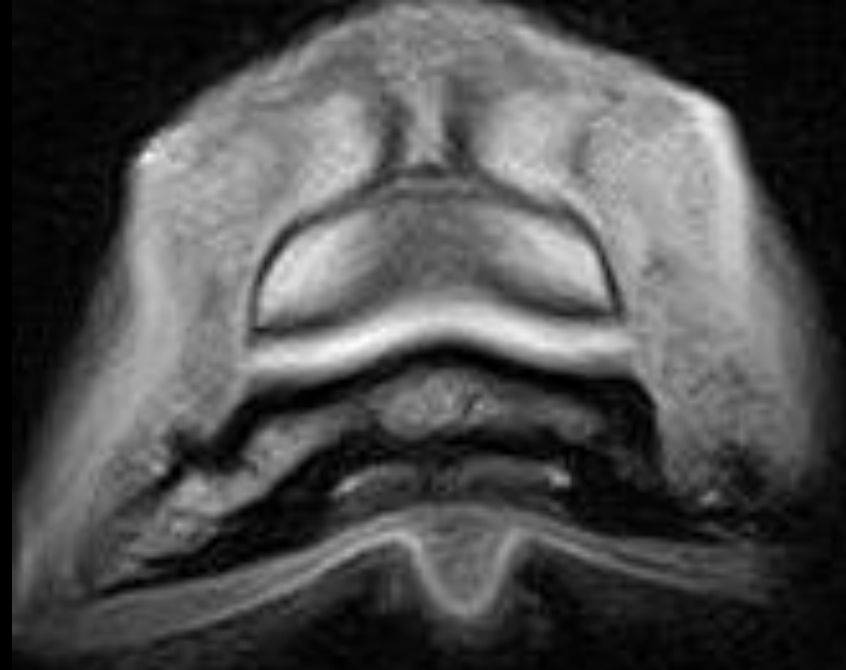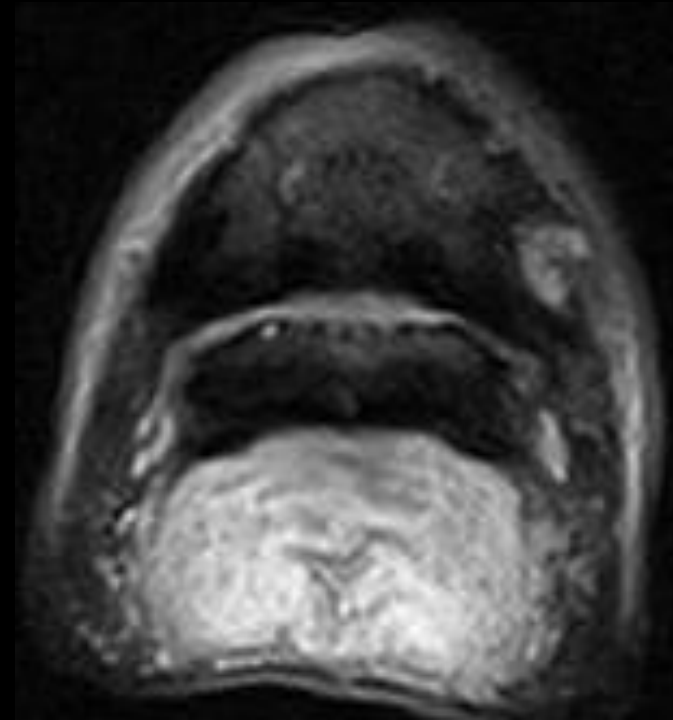
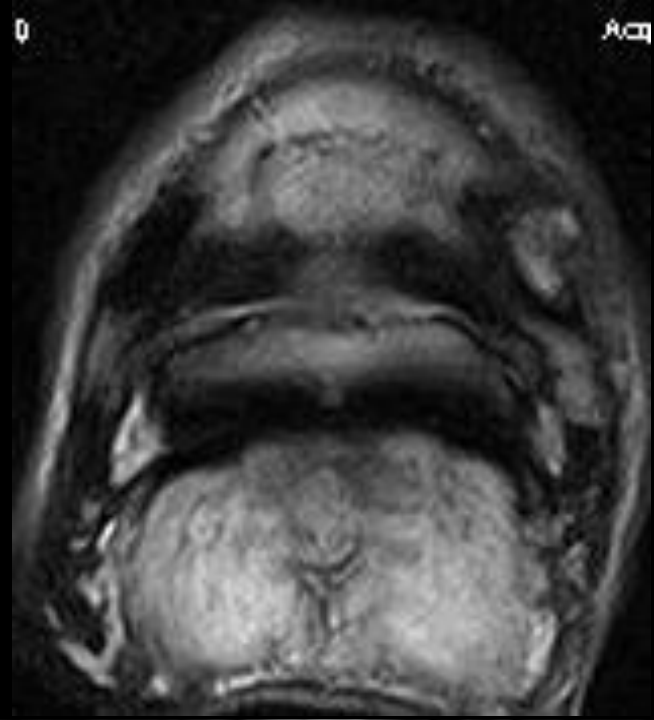
L





0

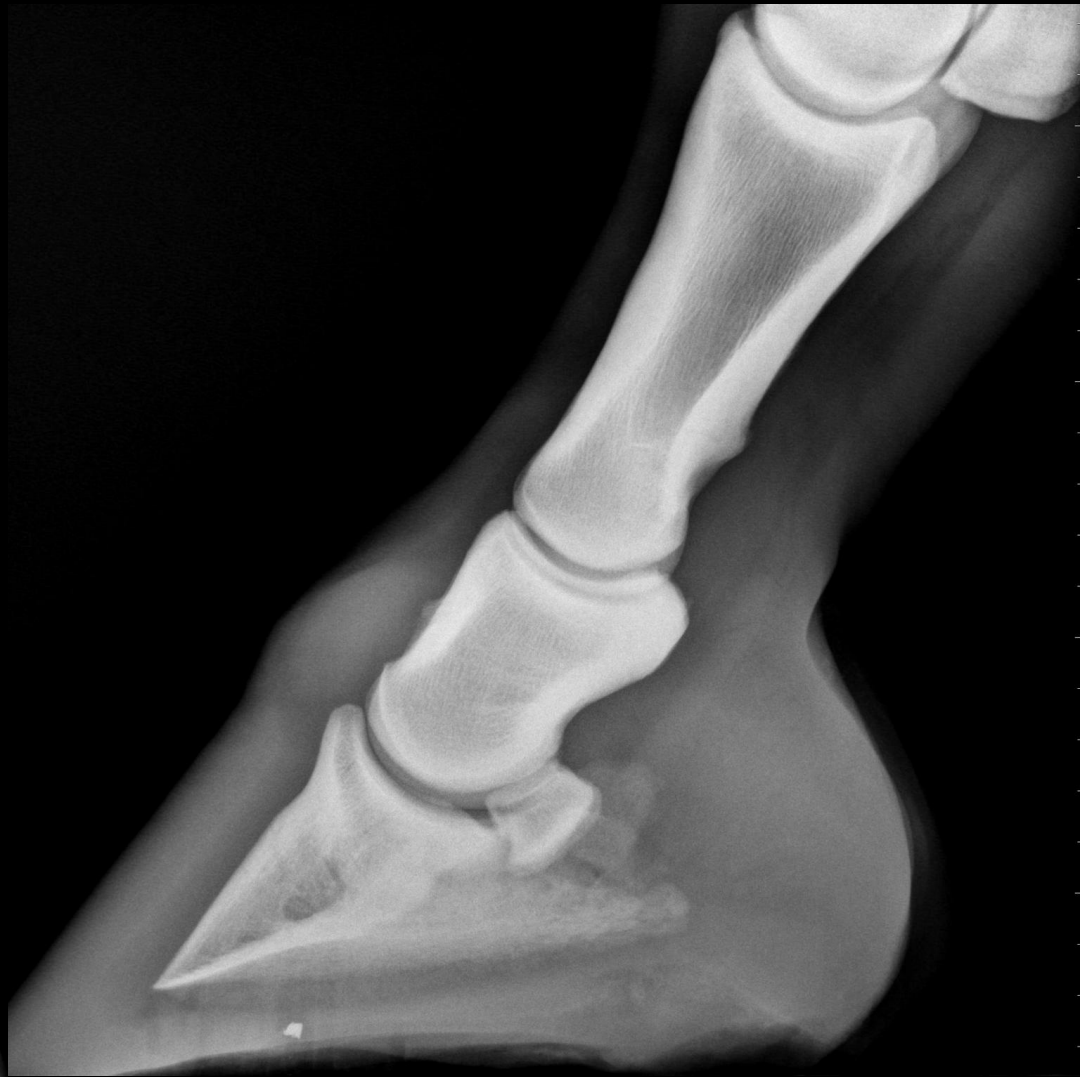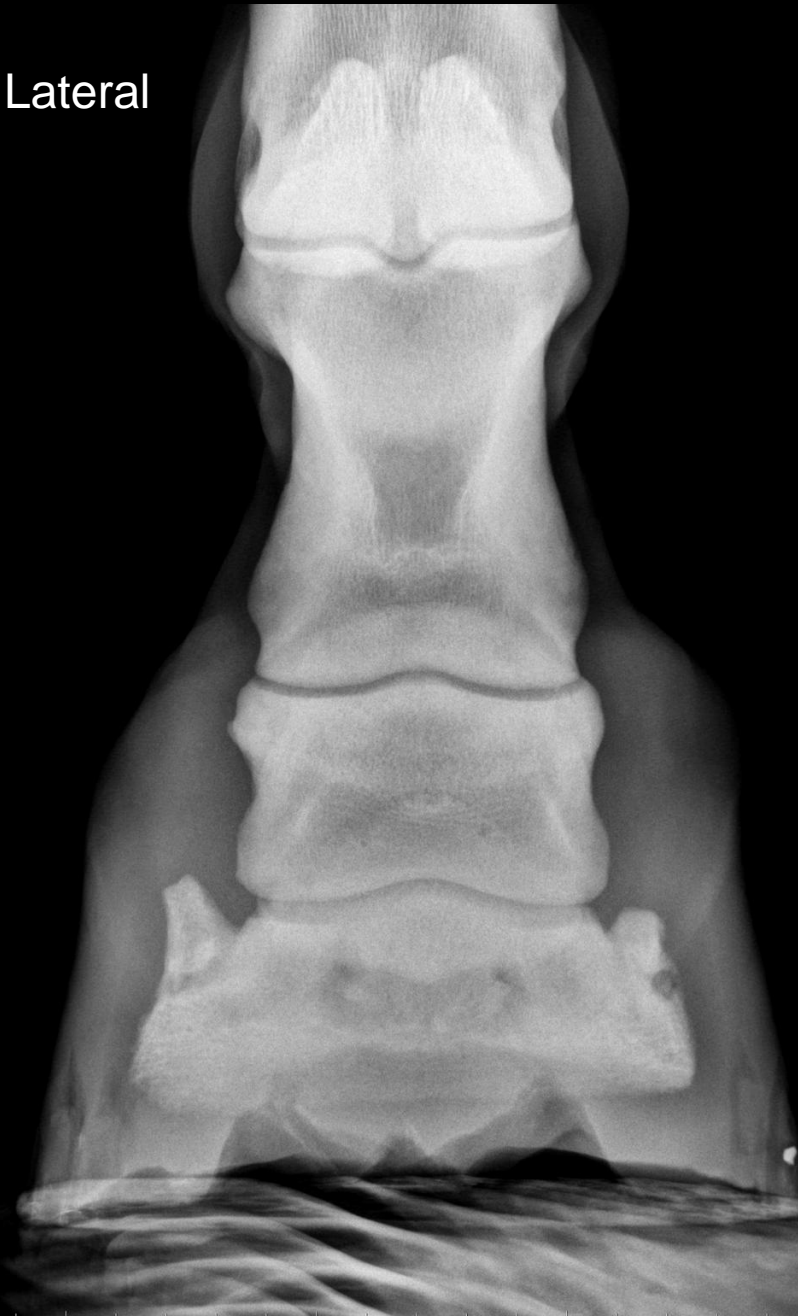Ac



# Case 2

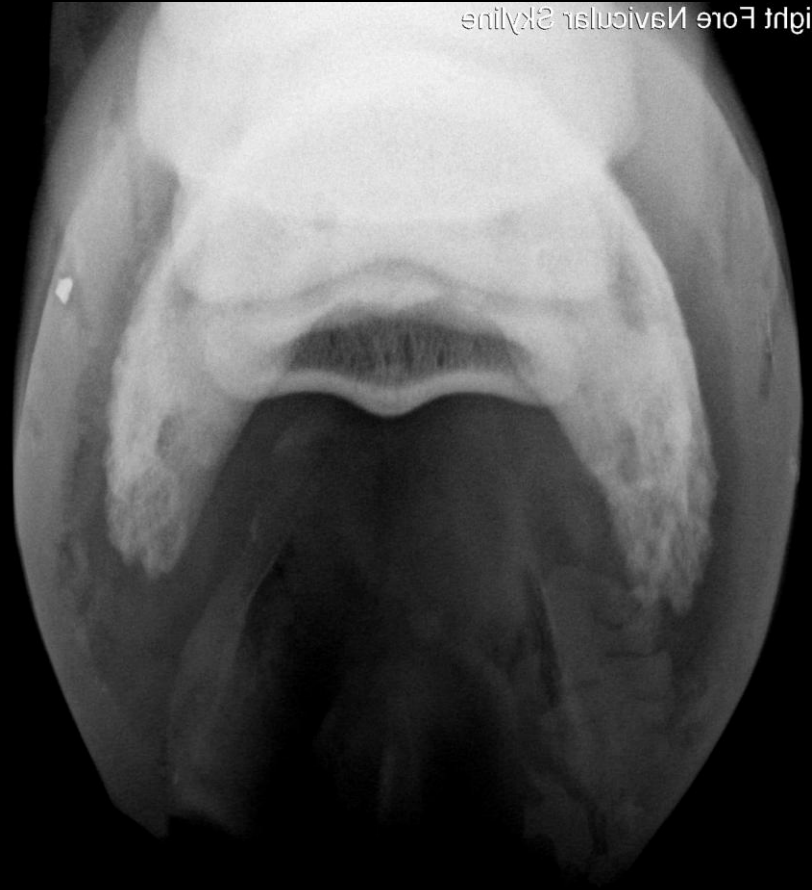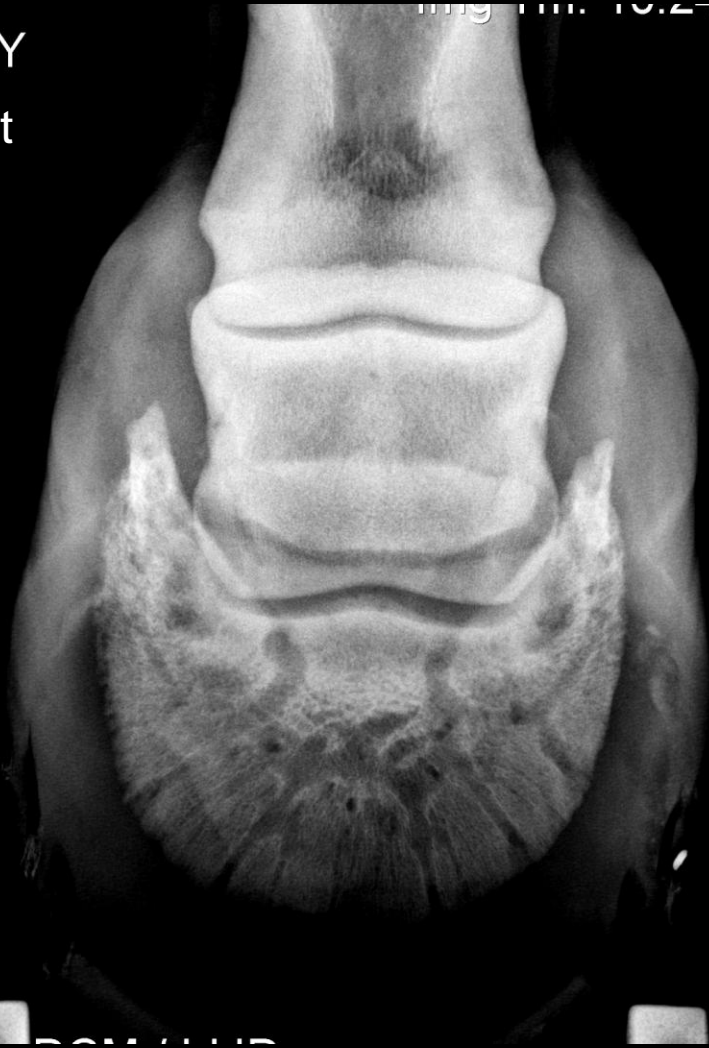- 6 yo WB Dressage Horse
- Lamé RF of 3 weeks duration
- Rest and bute improved lameness
- Lamé again once returned to work
- PD block 70% improvement
- Lameness resolved with abaxial nerve block

Lateral

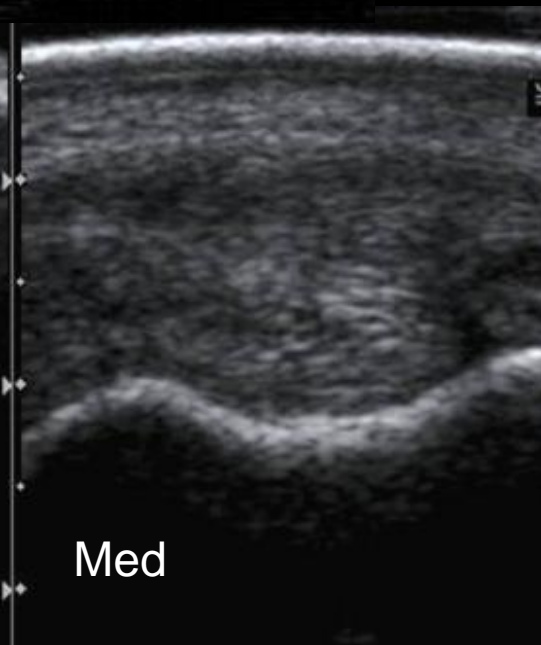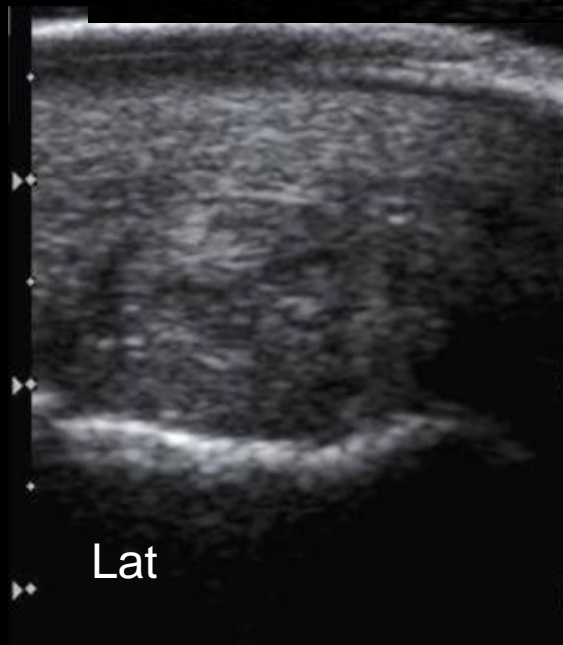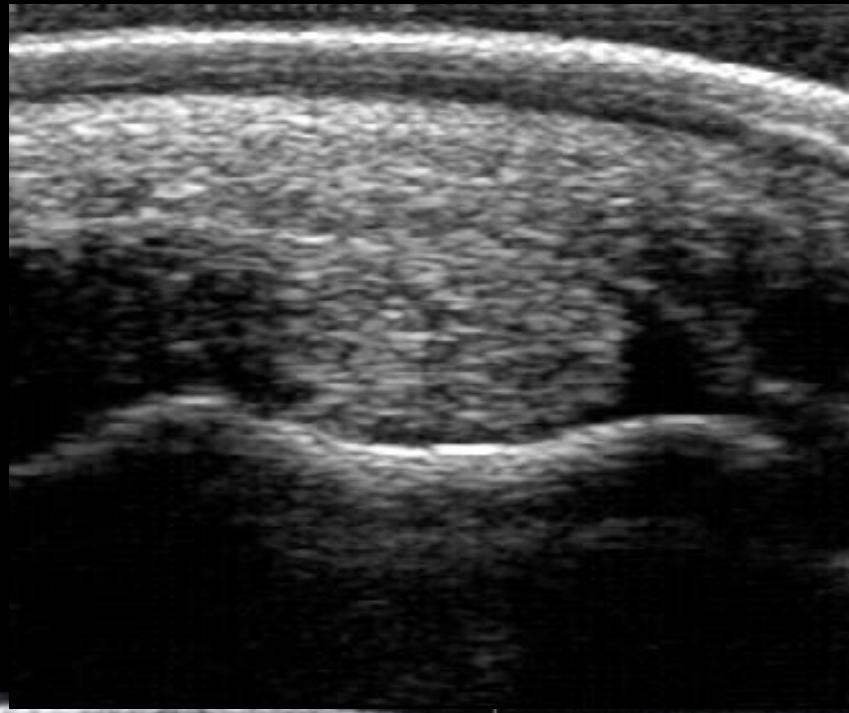


Courtesy of Dr. Natasha Werpy

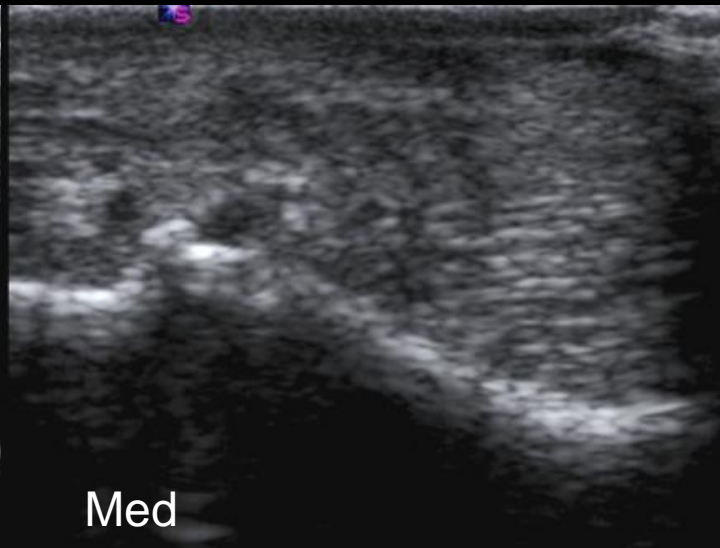
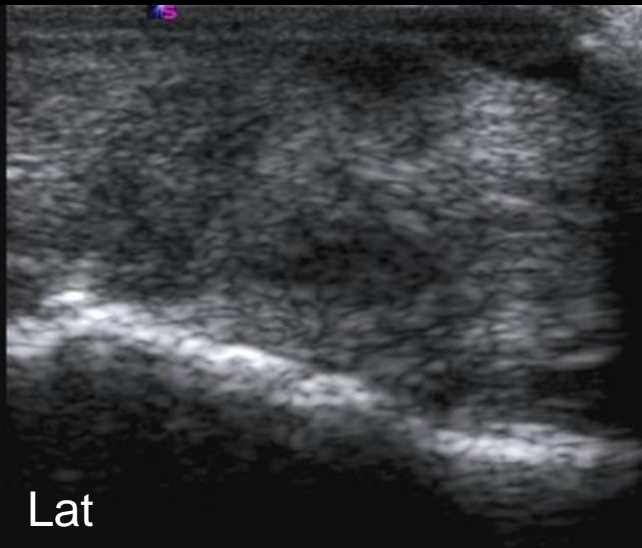
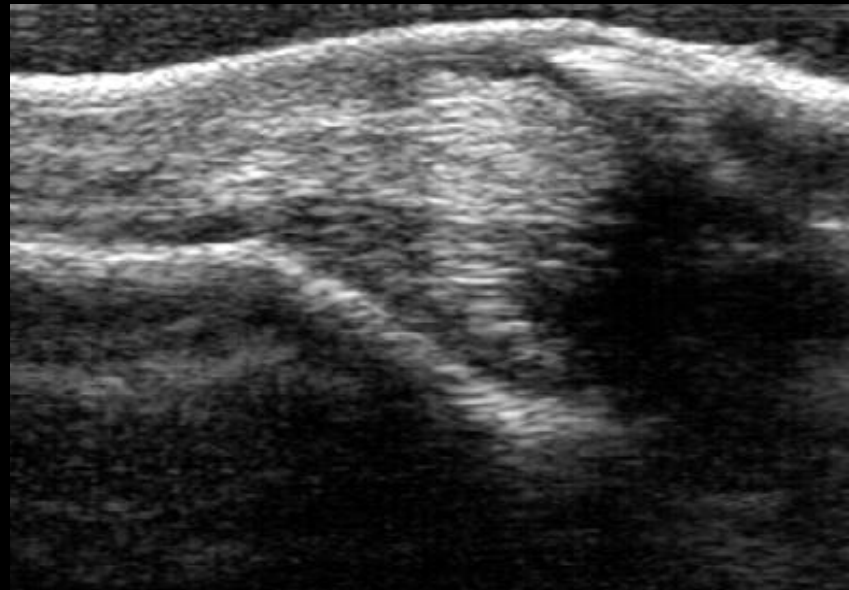
MITY  
Lat



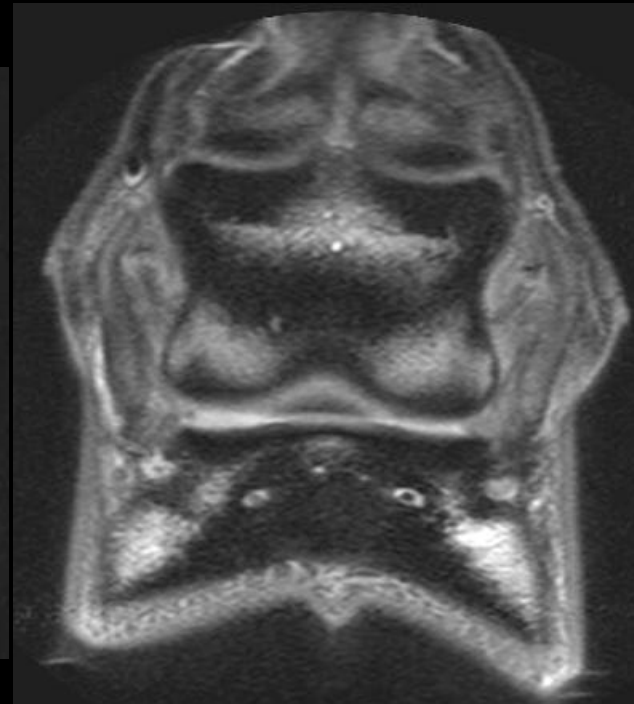
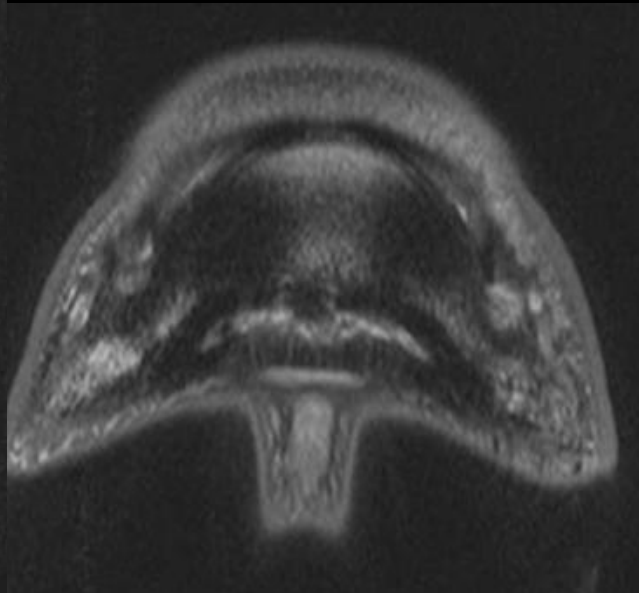
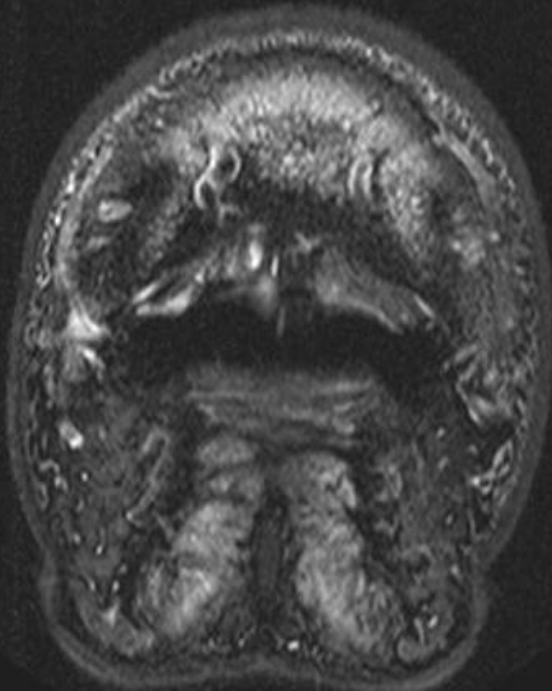Courtesy of Dr. Natasha Werpy



Courtesy of Dr. Natasha Werpy



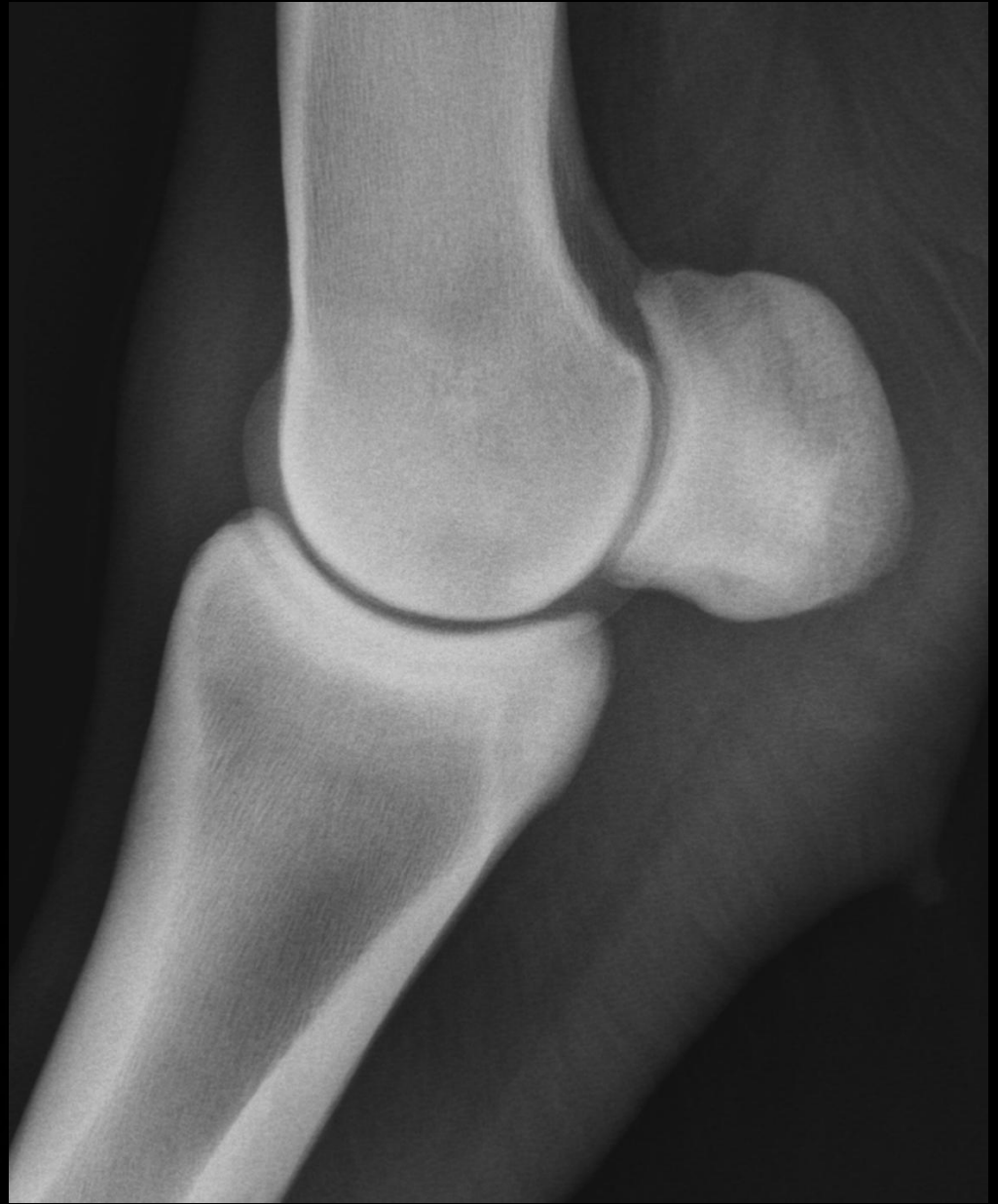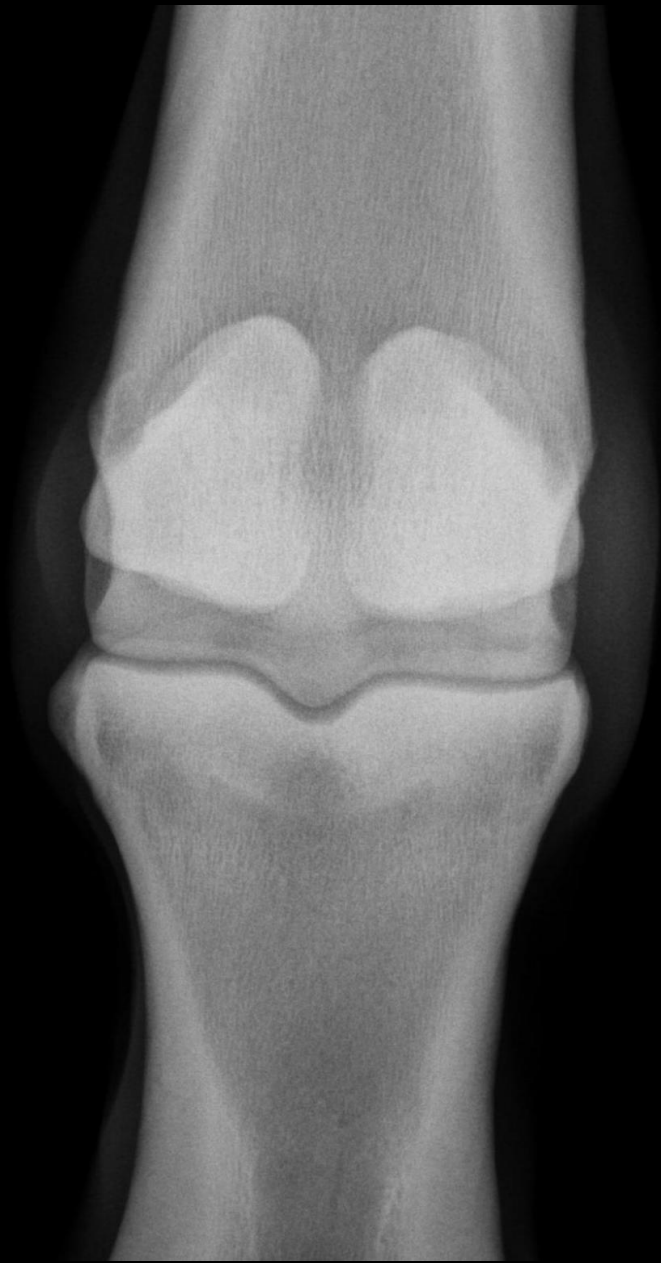Courtesy of Dr. Natasha Werpy

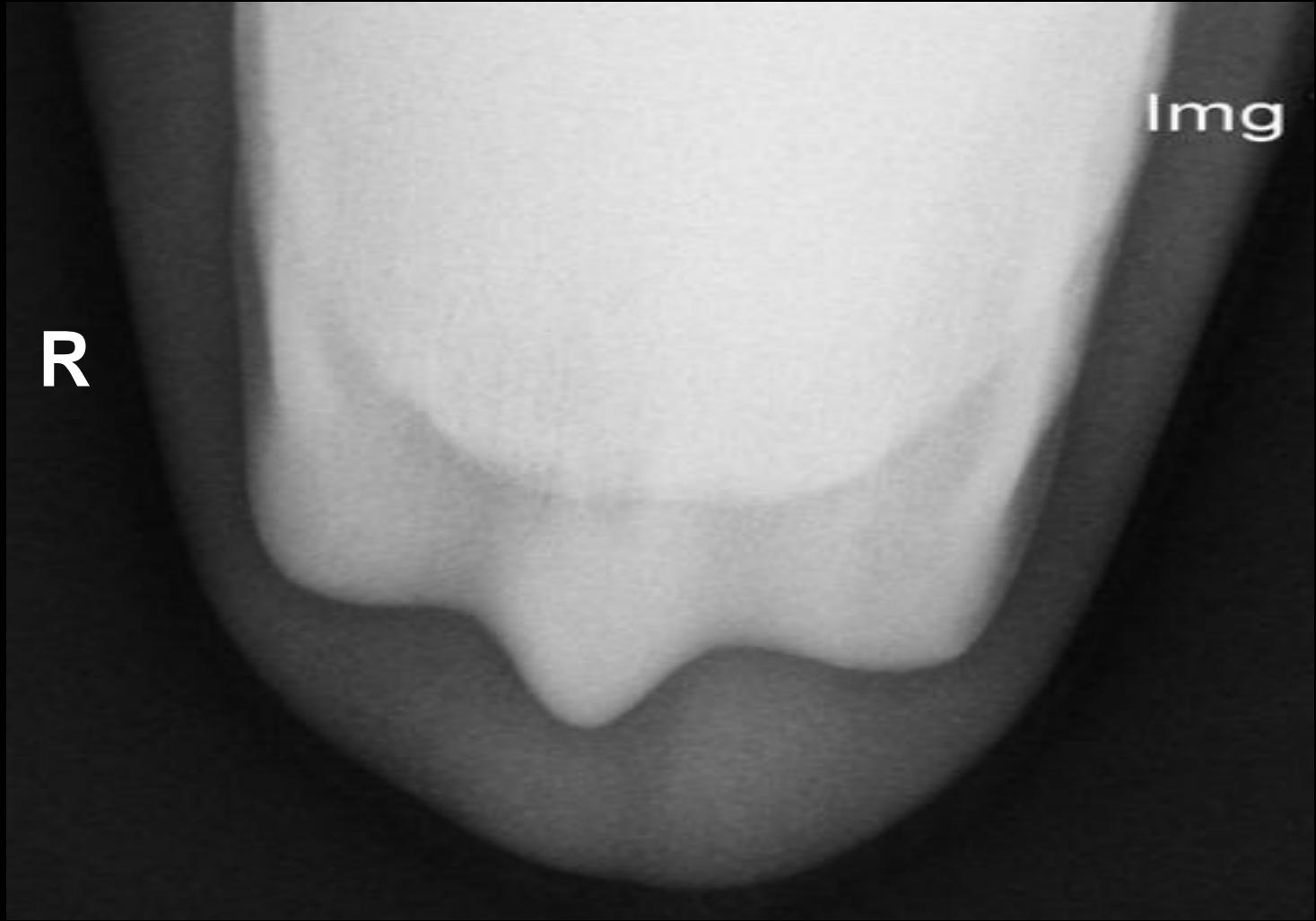


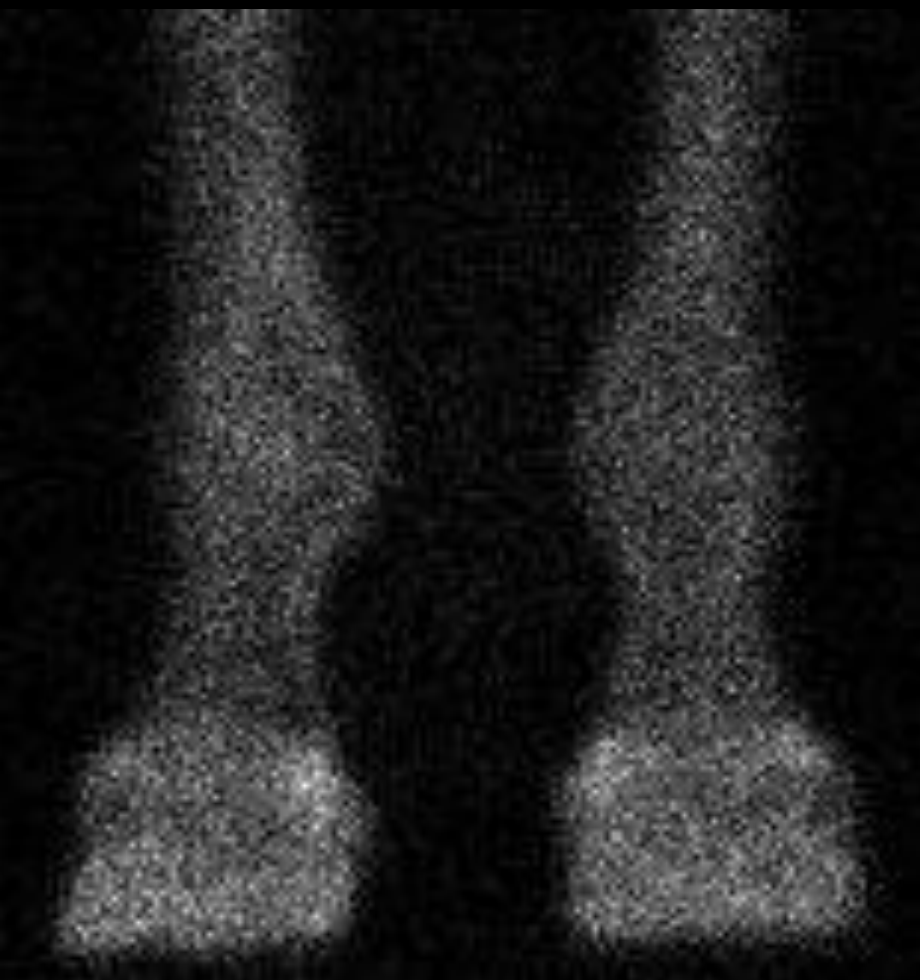Courtesy of Dr. Natasha Werpy

# Case 3

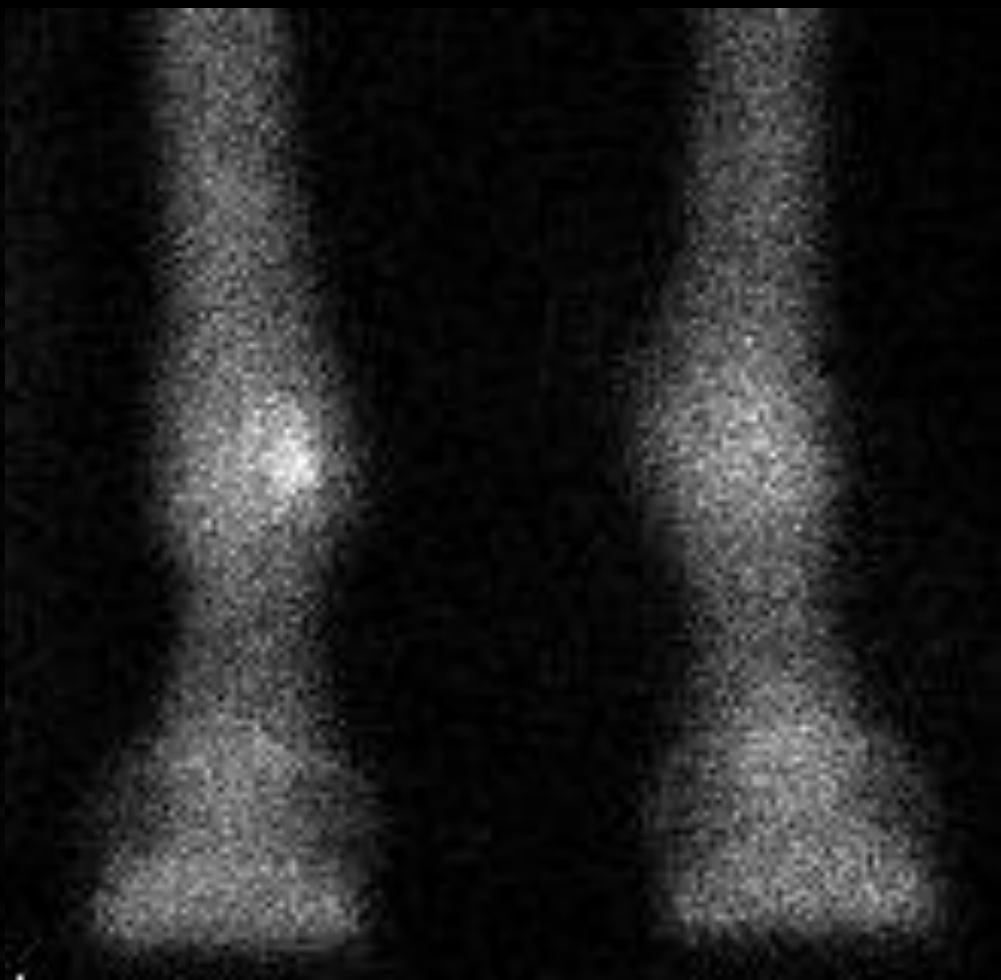
- 12 yr-old WB mare
- Show Jumper
- Slow progressive low-grade RF lameness for 3 months, 3/5 for last month
- Some response to NSAID's
- No response to PD and abaxial
- Significant improvement to low 4 point



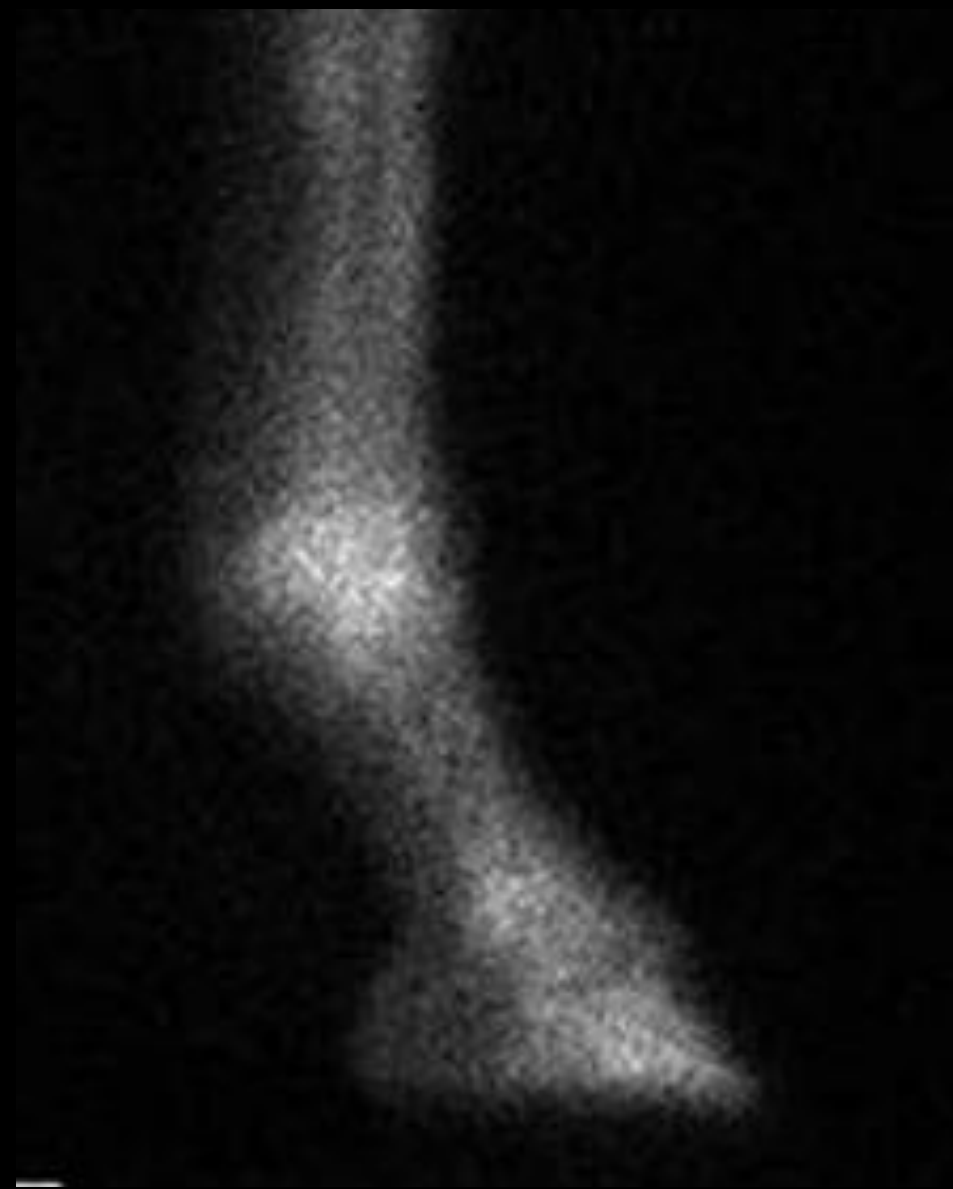




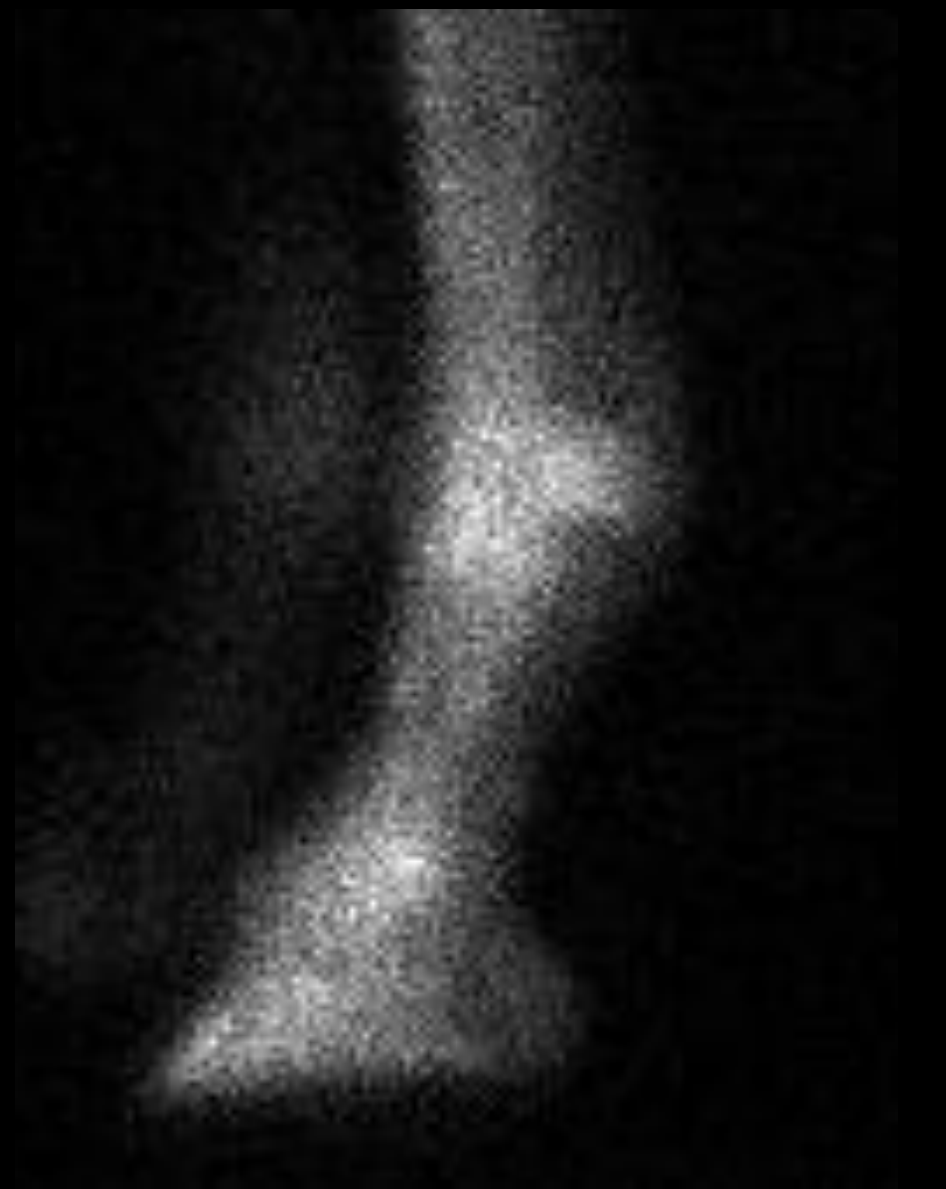**SOFT TISSUE**



**BONE**

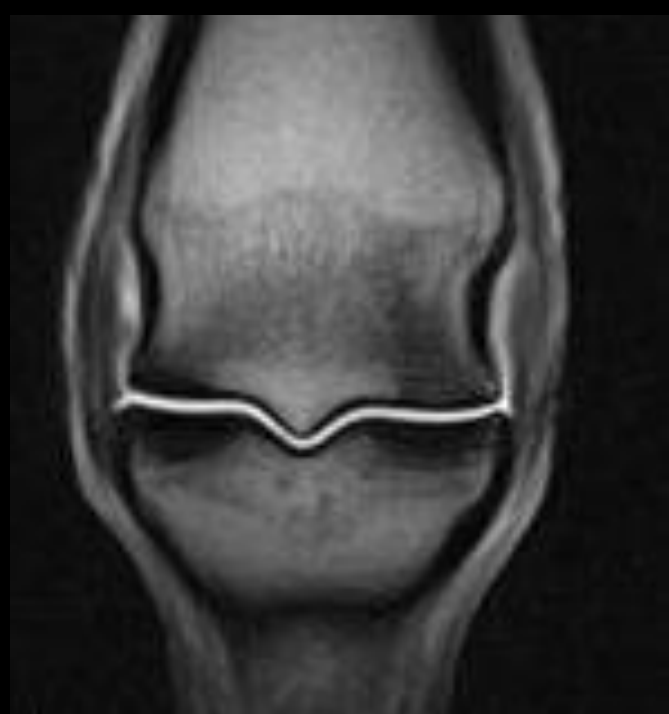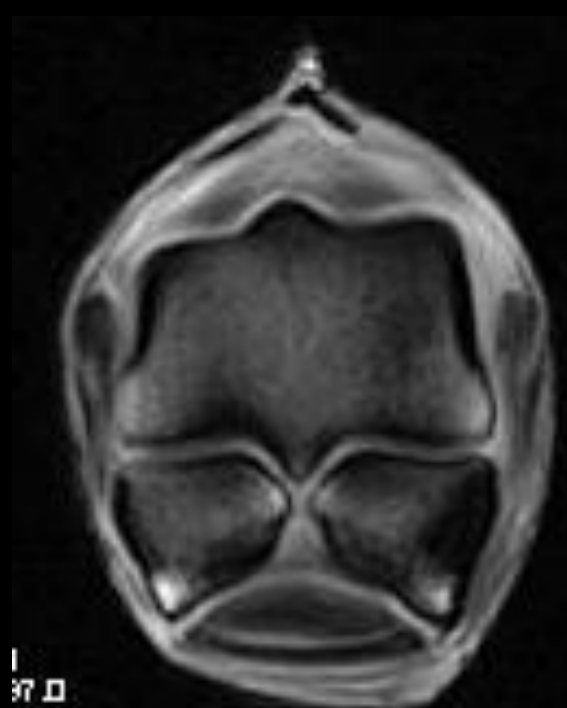


R

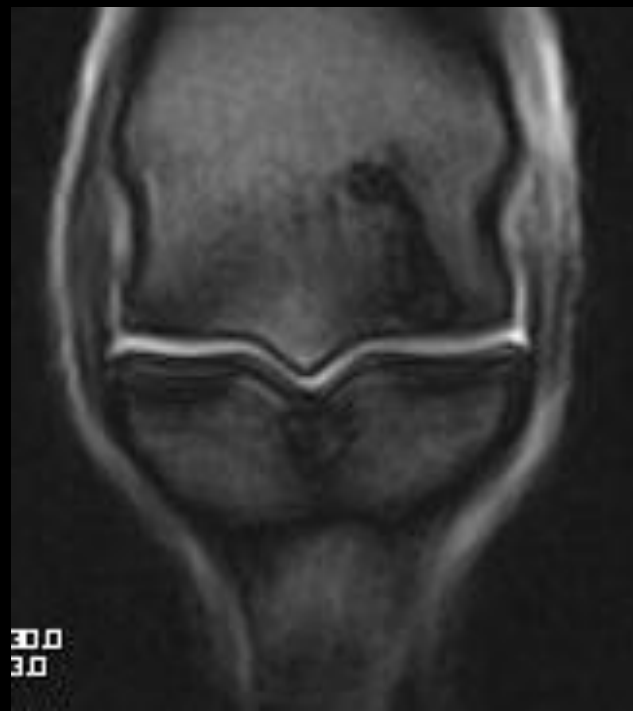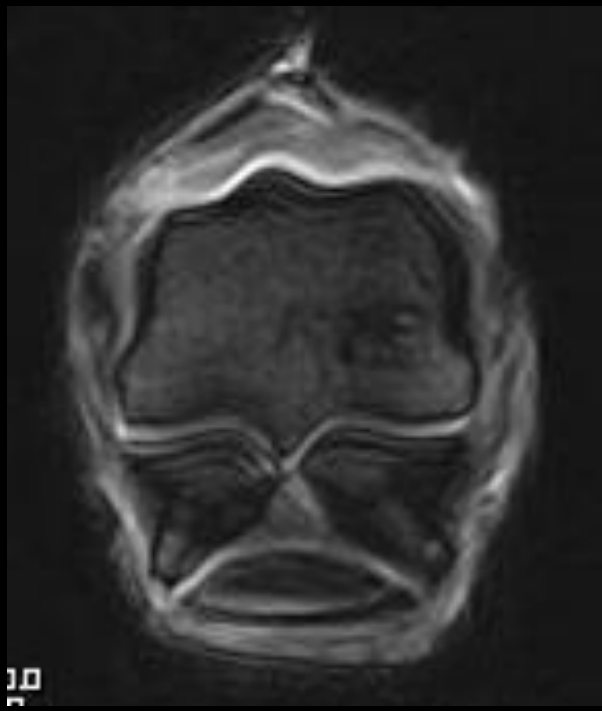


L

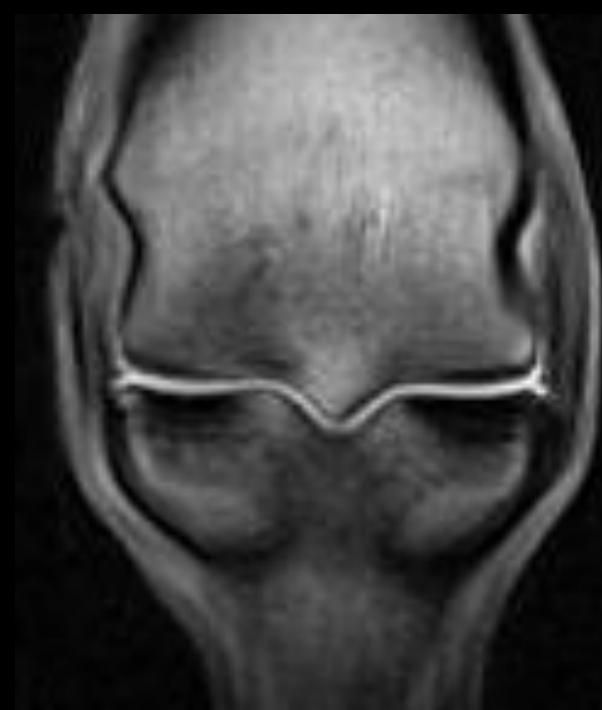T1



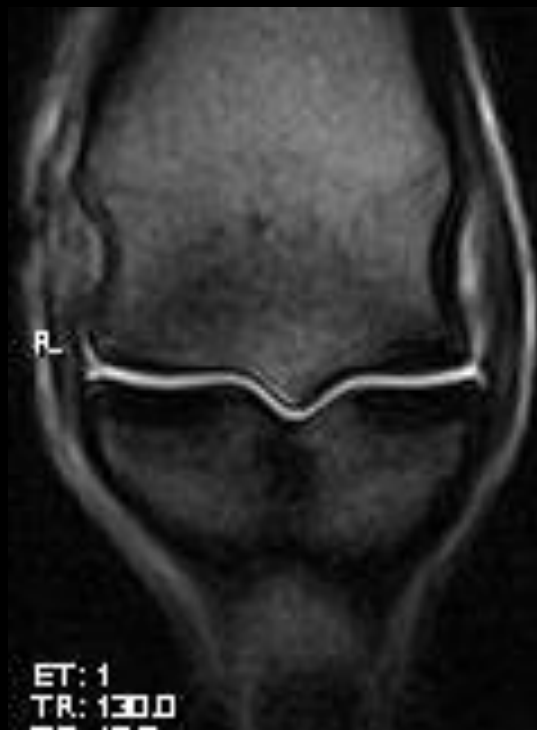T2



LF

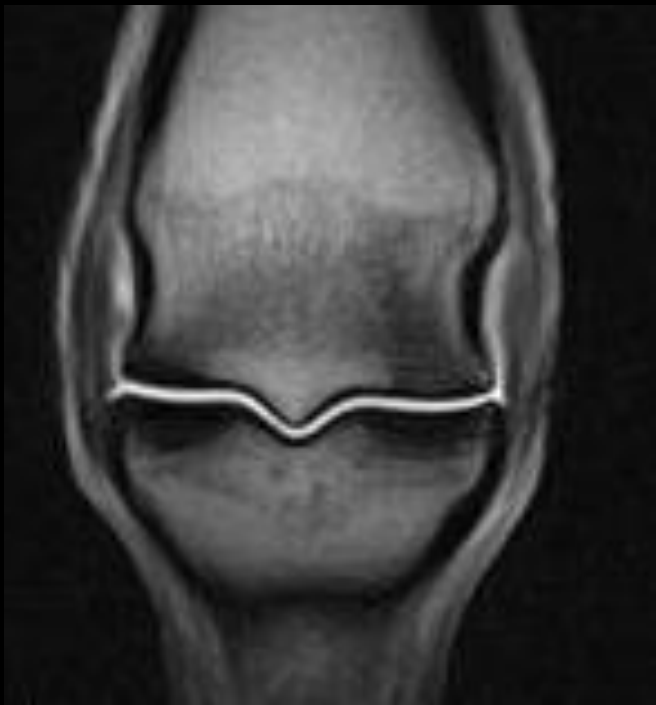

R

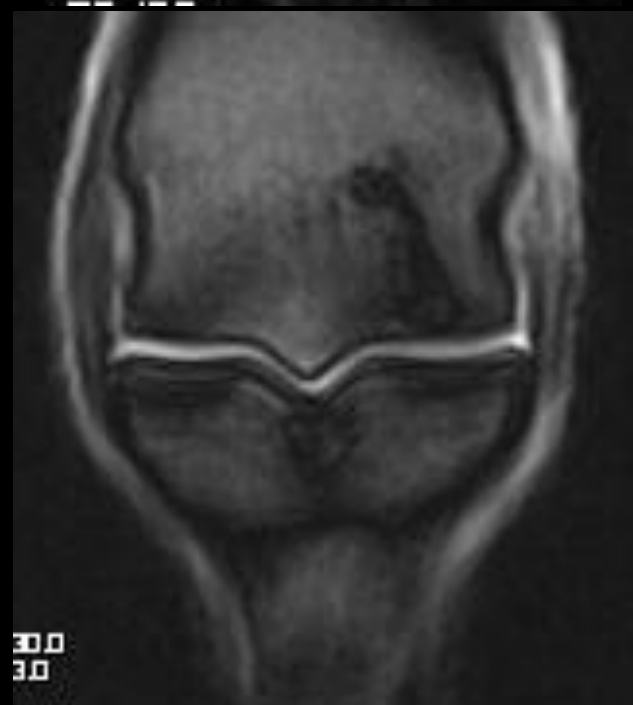

ET: 1  
TR: 130.0

RF

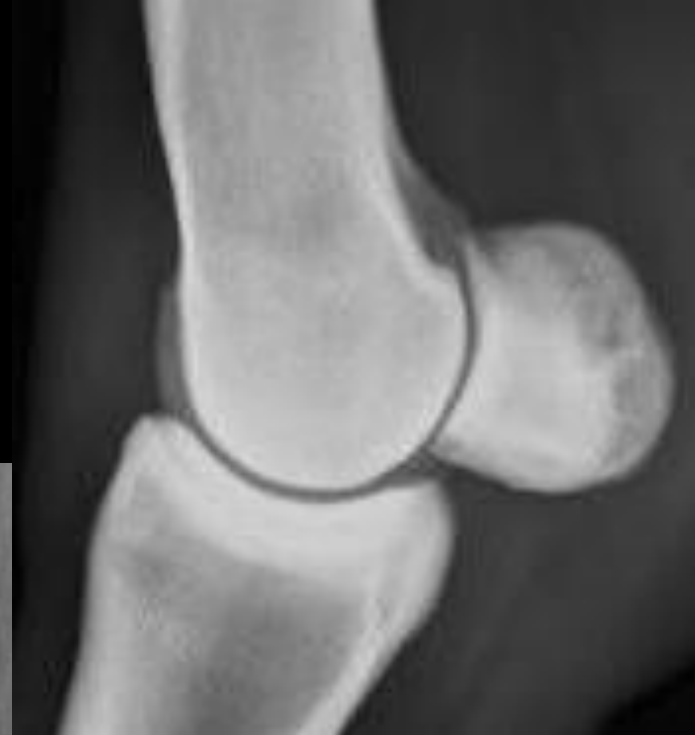
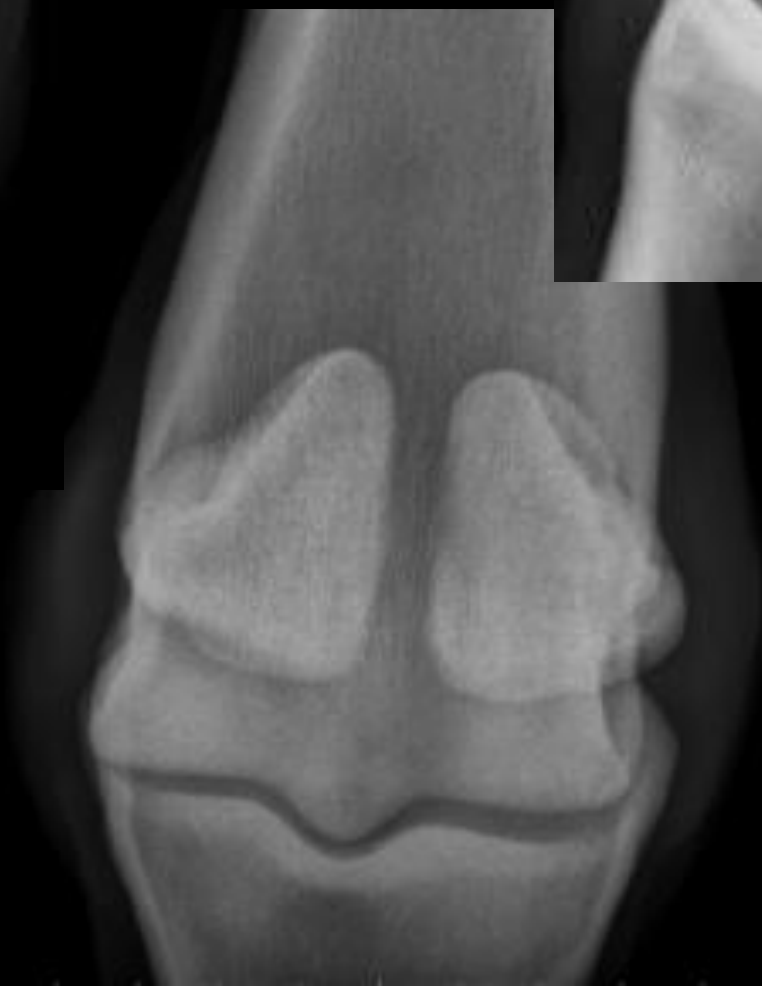
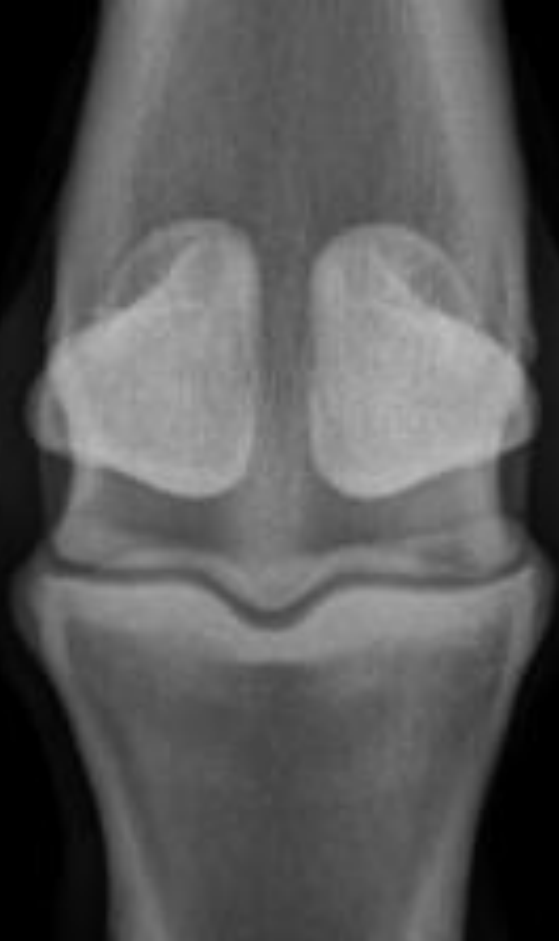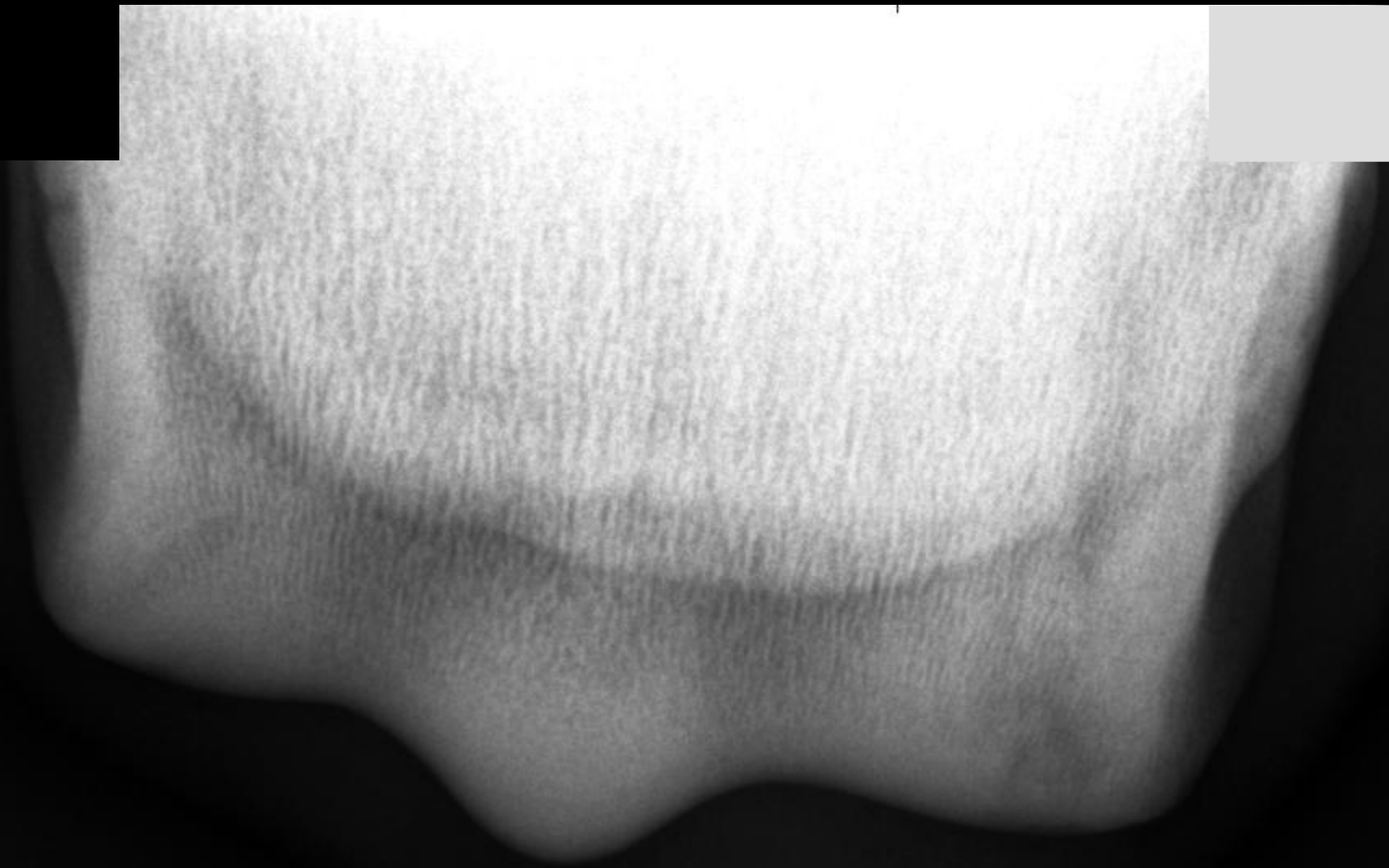30.0  
3.0



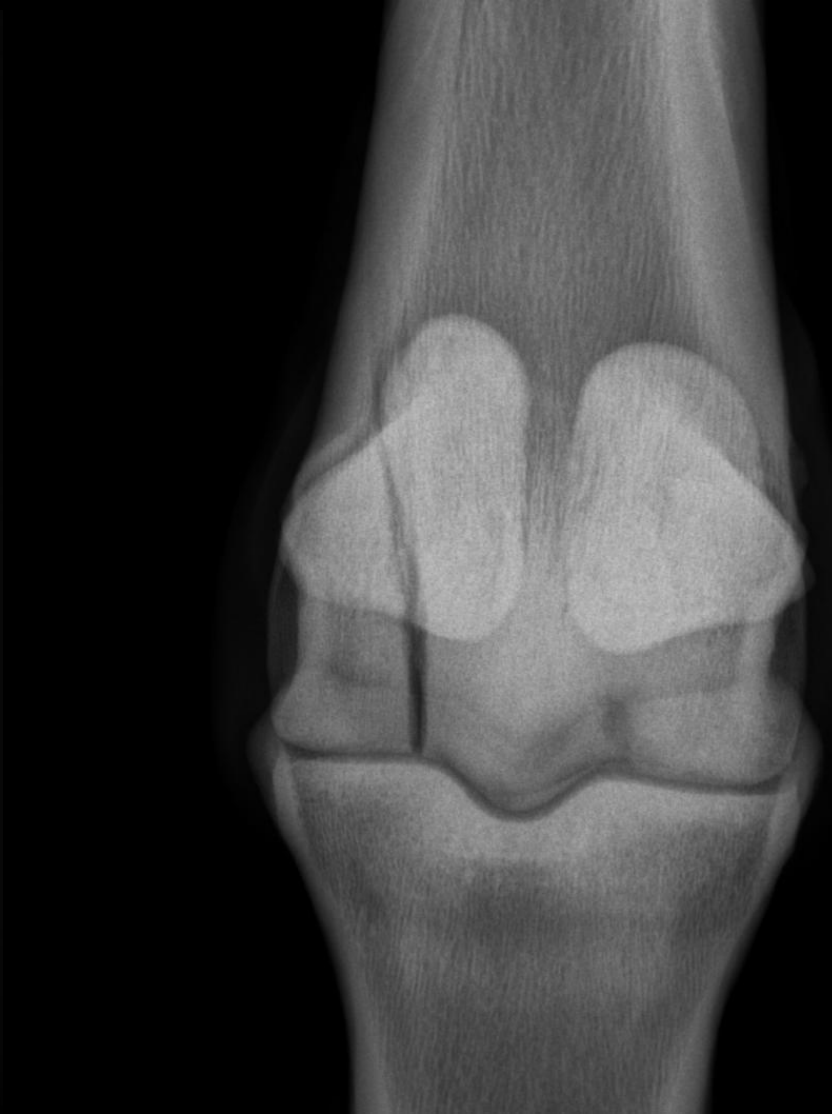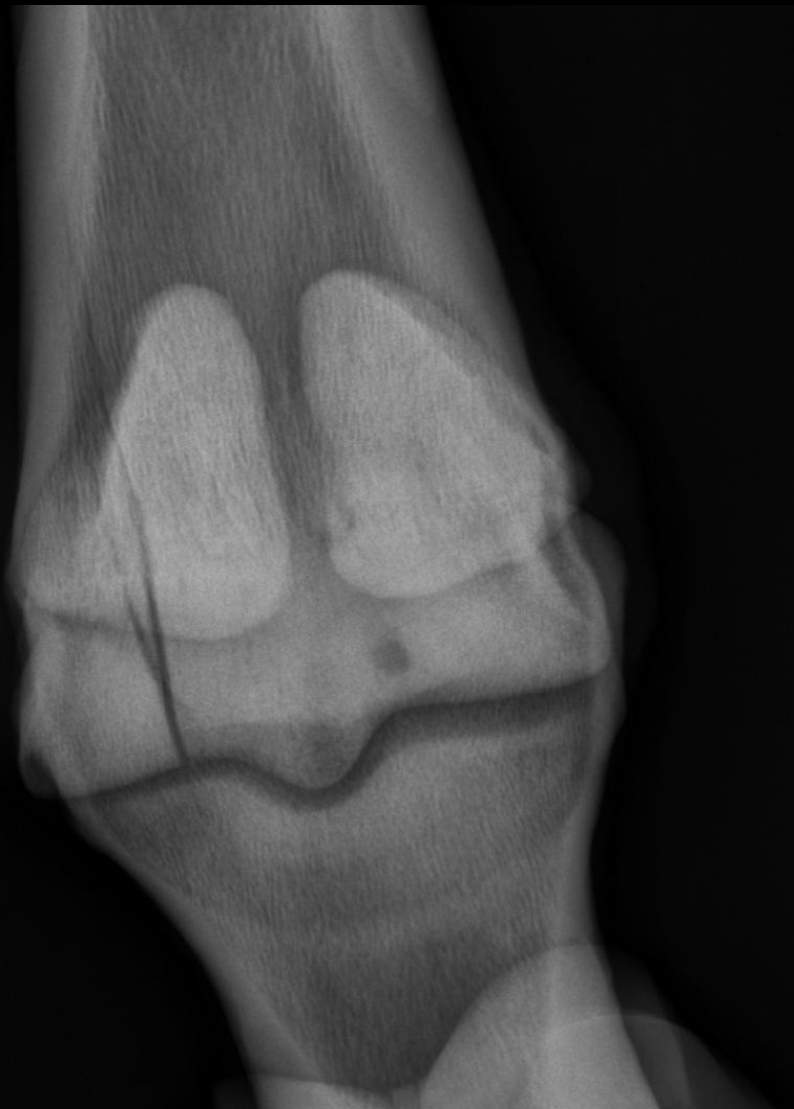# Case 4

- 8 yr old THB gelding
- Retired racehorse used for 3-day eventing
- 2-3/5 lame on right front for 4-6 weeks
- Mild fetlock effusion
- Very positive to fetlock flexion test
- PD and abaxial block → no response
- Significant improvement with intraarticular fetlock block



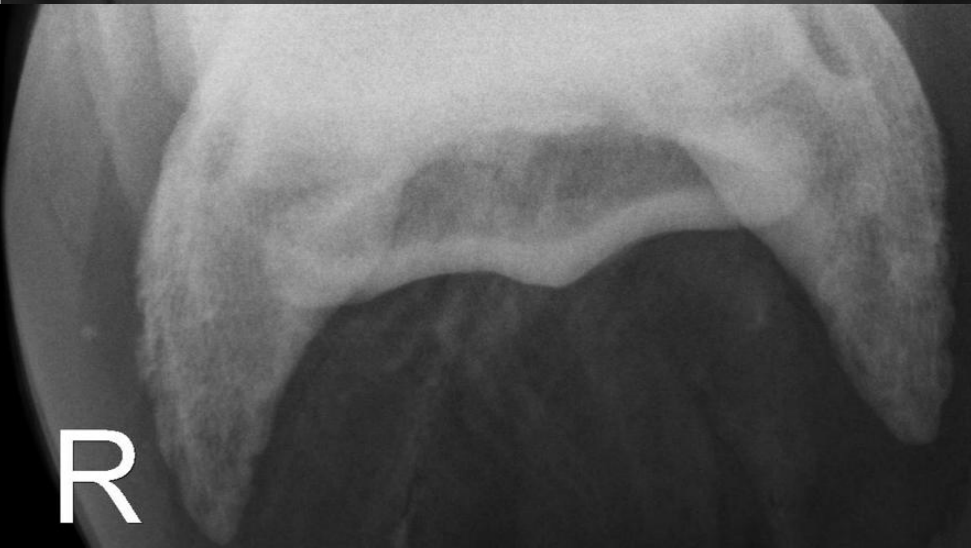
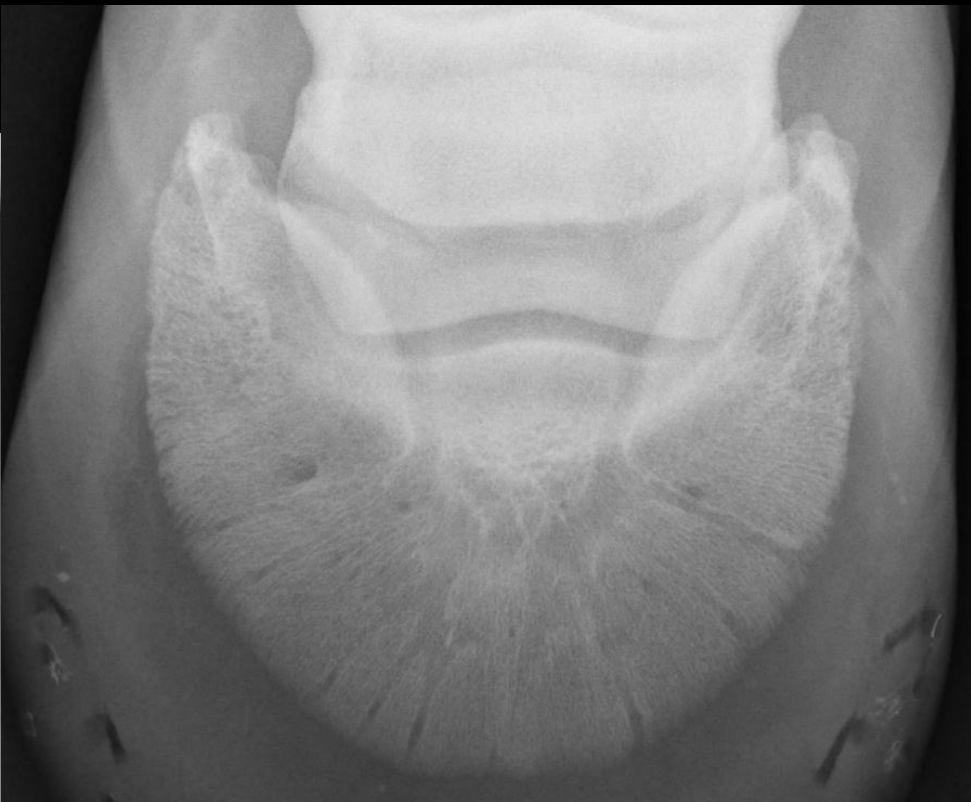
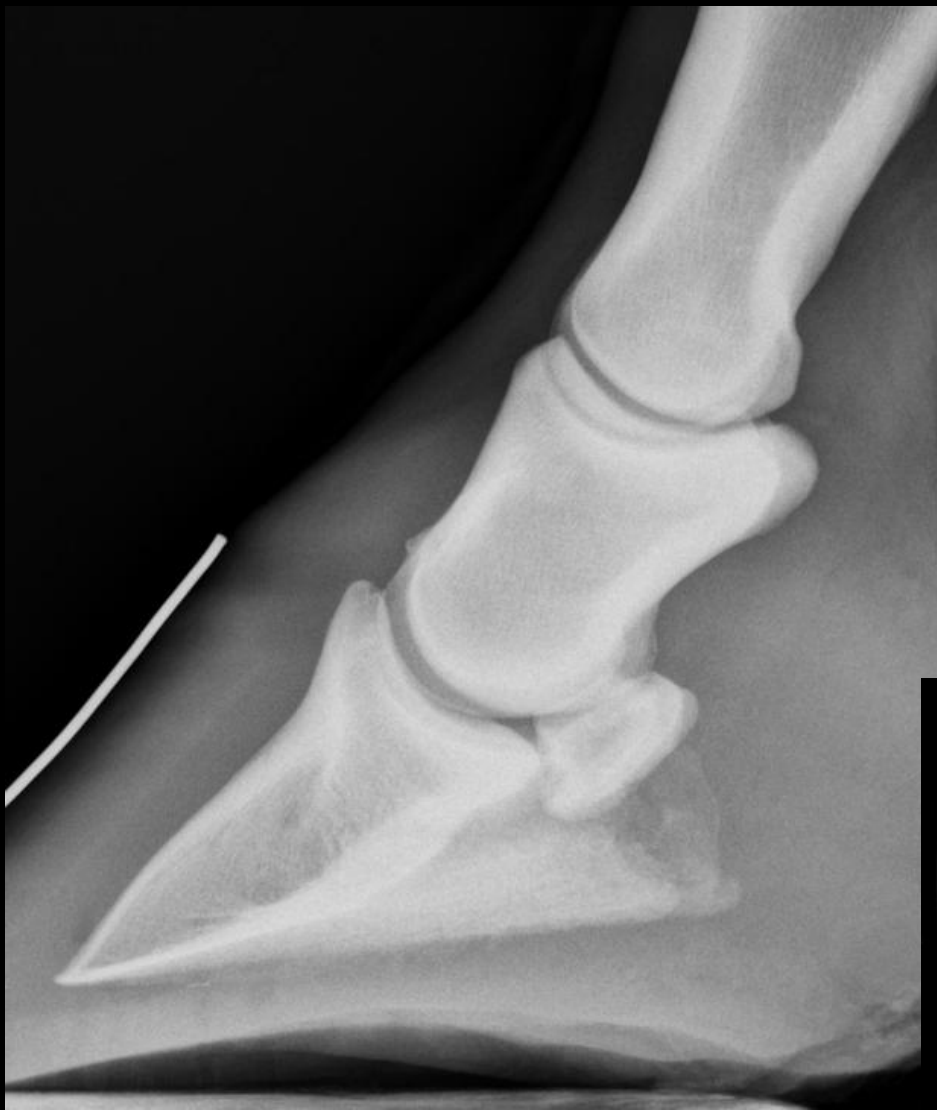# Condylar fracture and “cyst-like” lesion



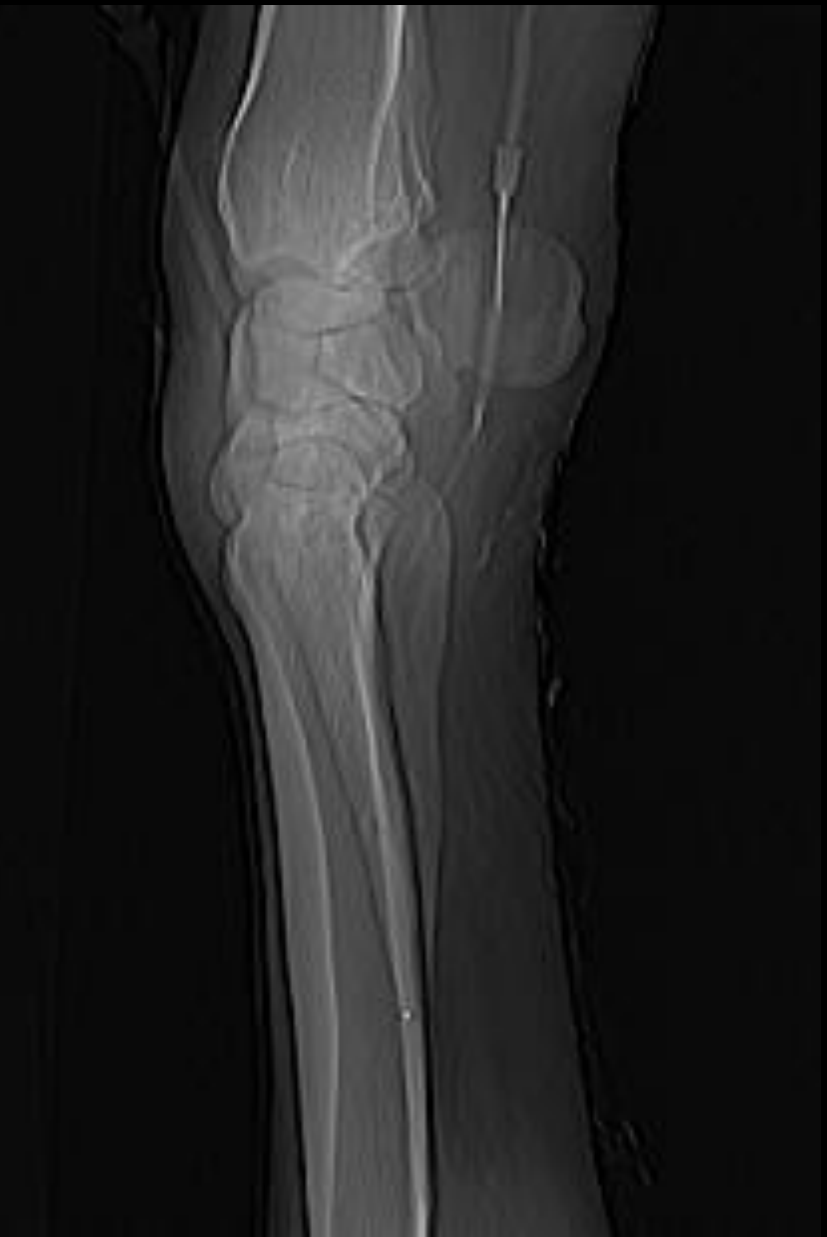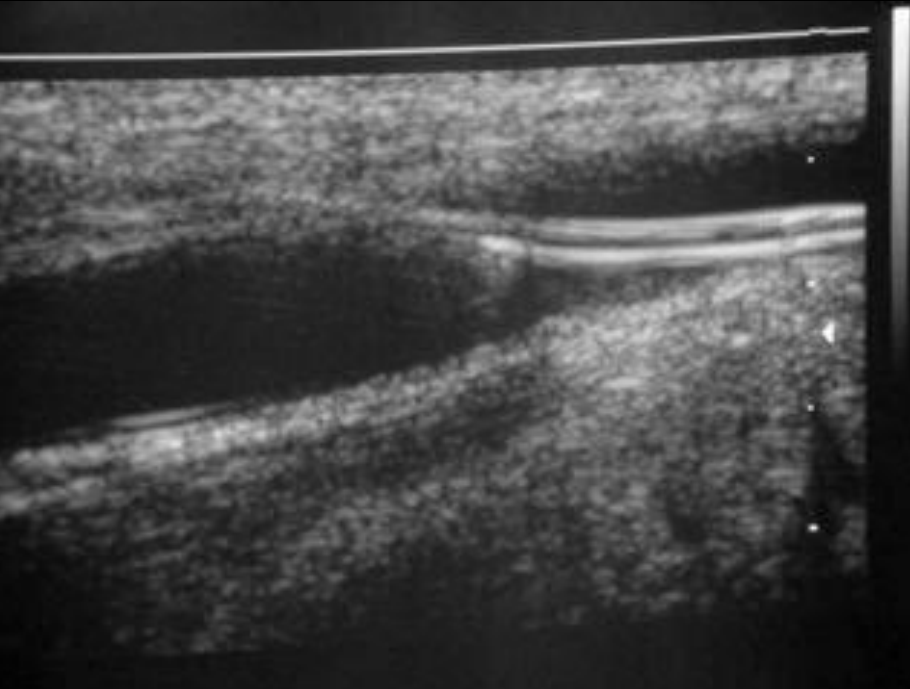
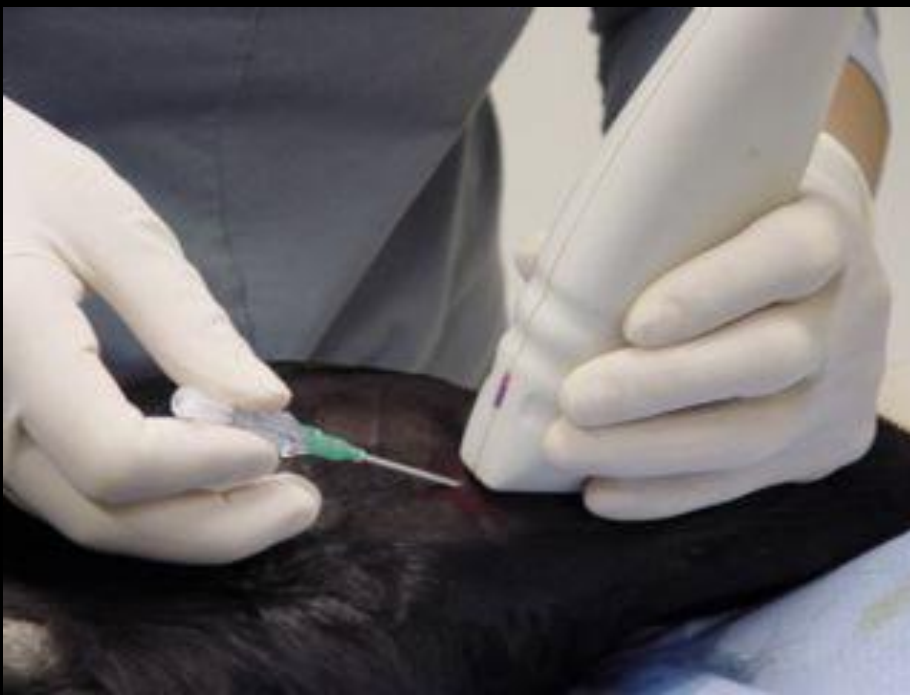# Case 5

- 8 yr-old WB gelding
- Show jumper
- 3-4 week 2-3/5 RF lameness
- Mild response to NSAID's
- Significant improvement to PD



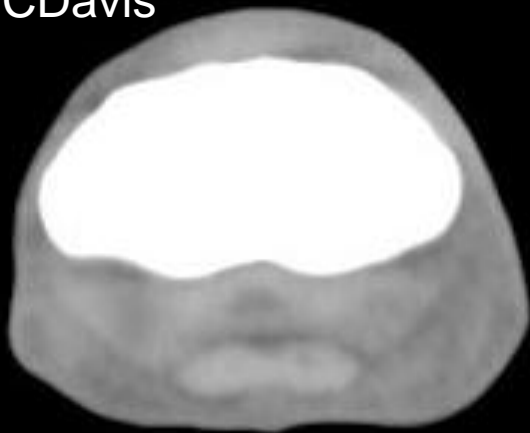
Courtesy of UC Davis

R

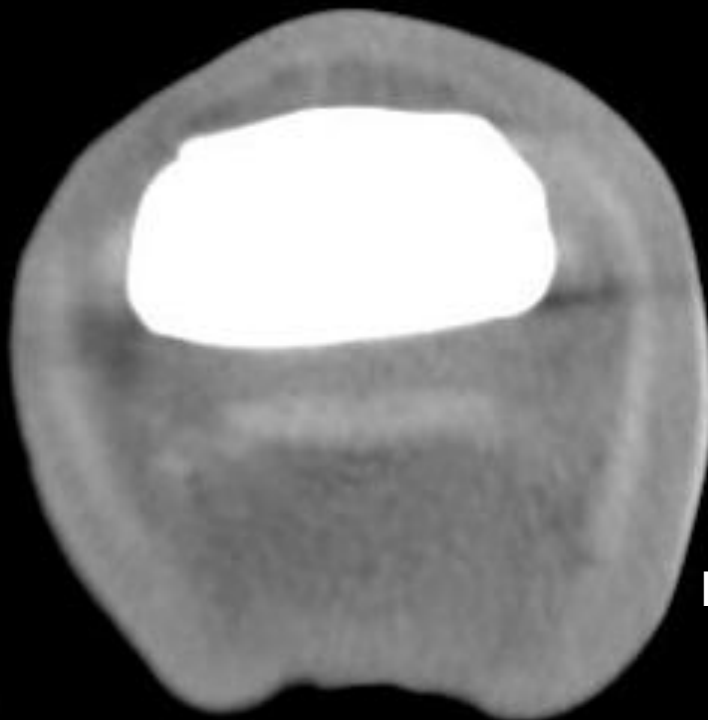
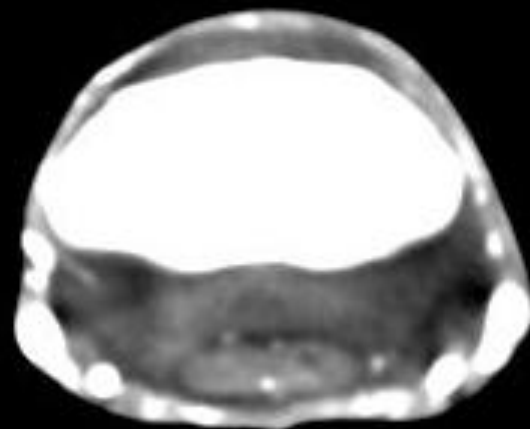


**Medial Palmar Artery**

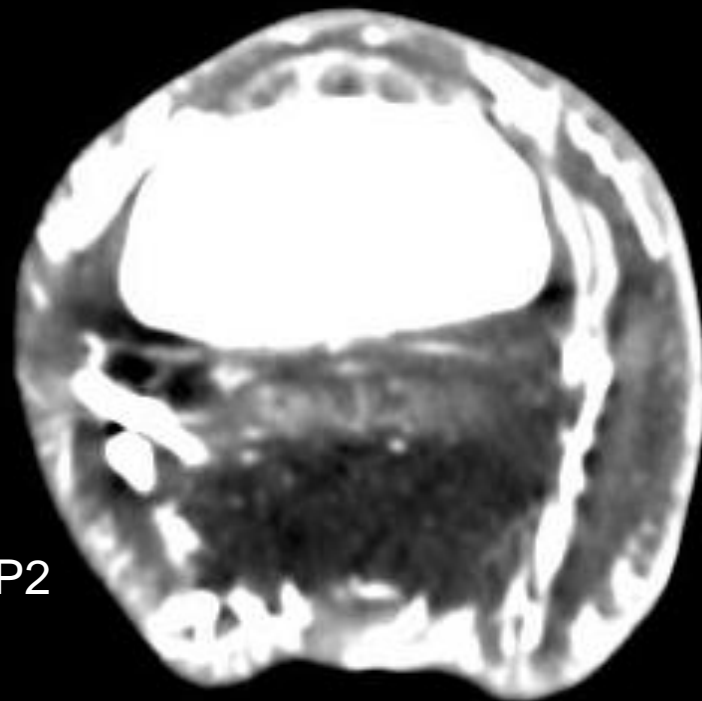
Courtesy of UCDavis



Distal P1



Distal P2

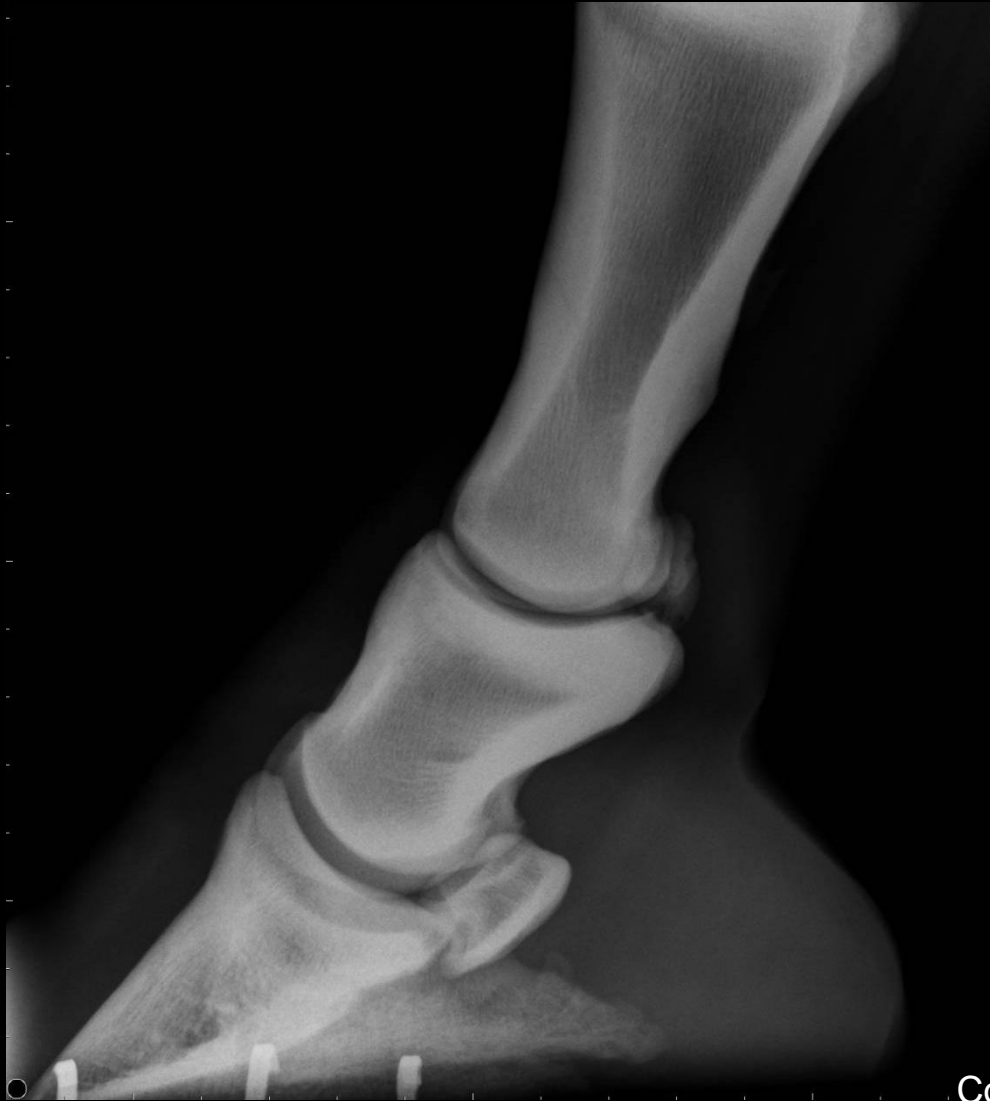

CT Pre contrast

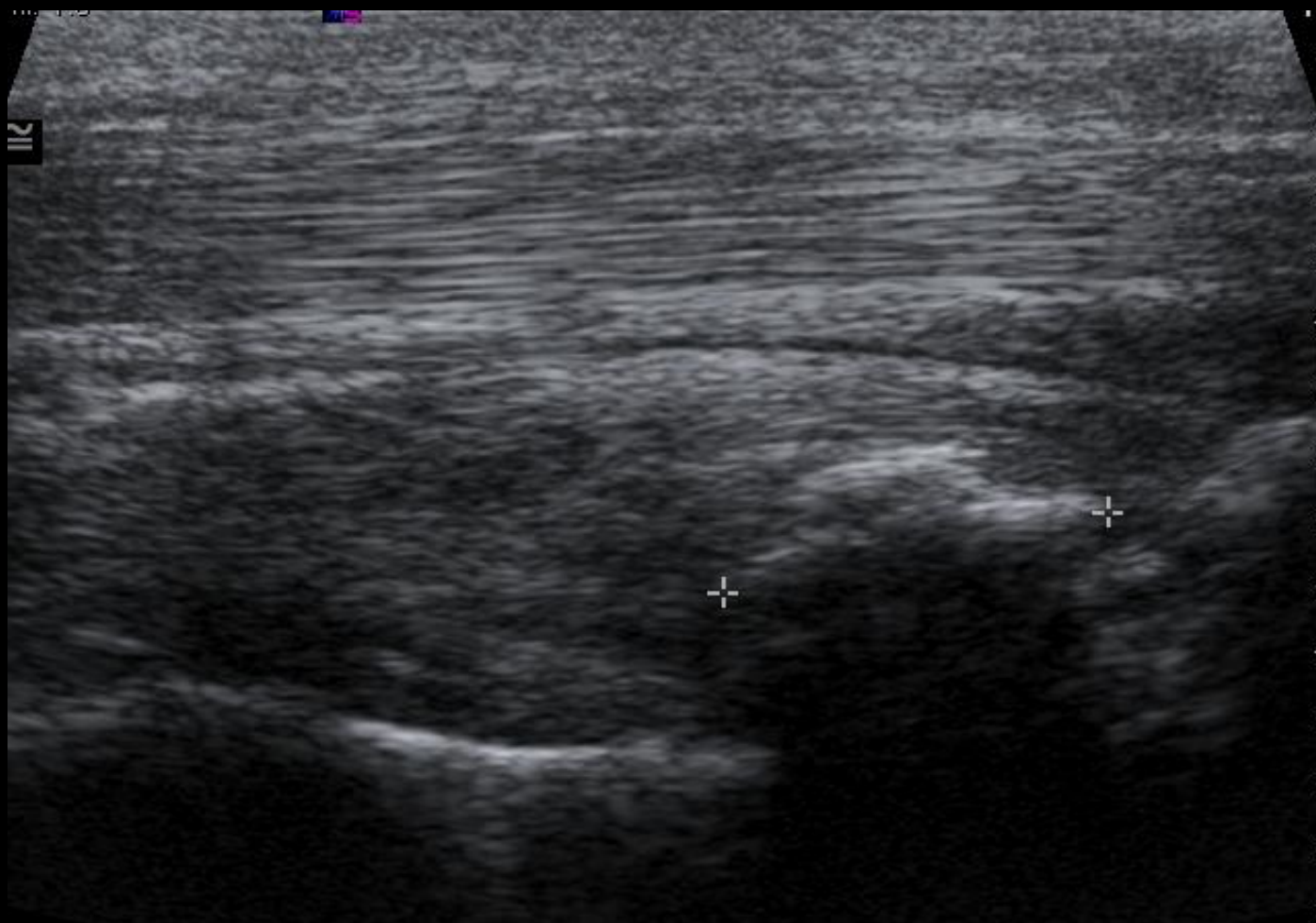
CT Post contrast

# Case 6

- 8 yr old Western performance gelding
- Acute lameness (3/5) 5-6 months prior to presentation
- Significant improvement with medical treatment and rest
- Intermittent lameness (1-2/5) for 6 weeks

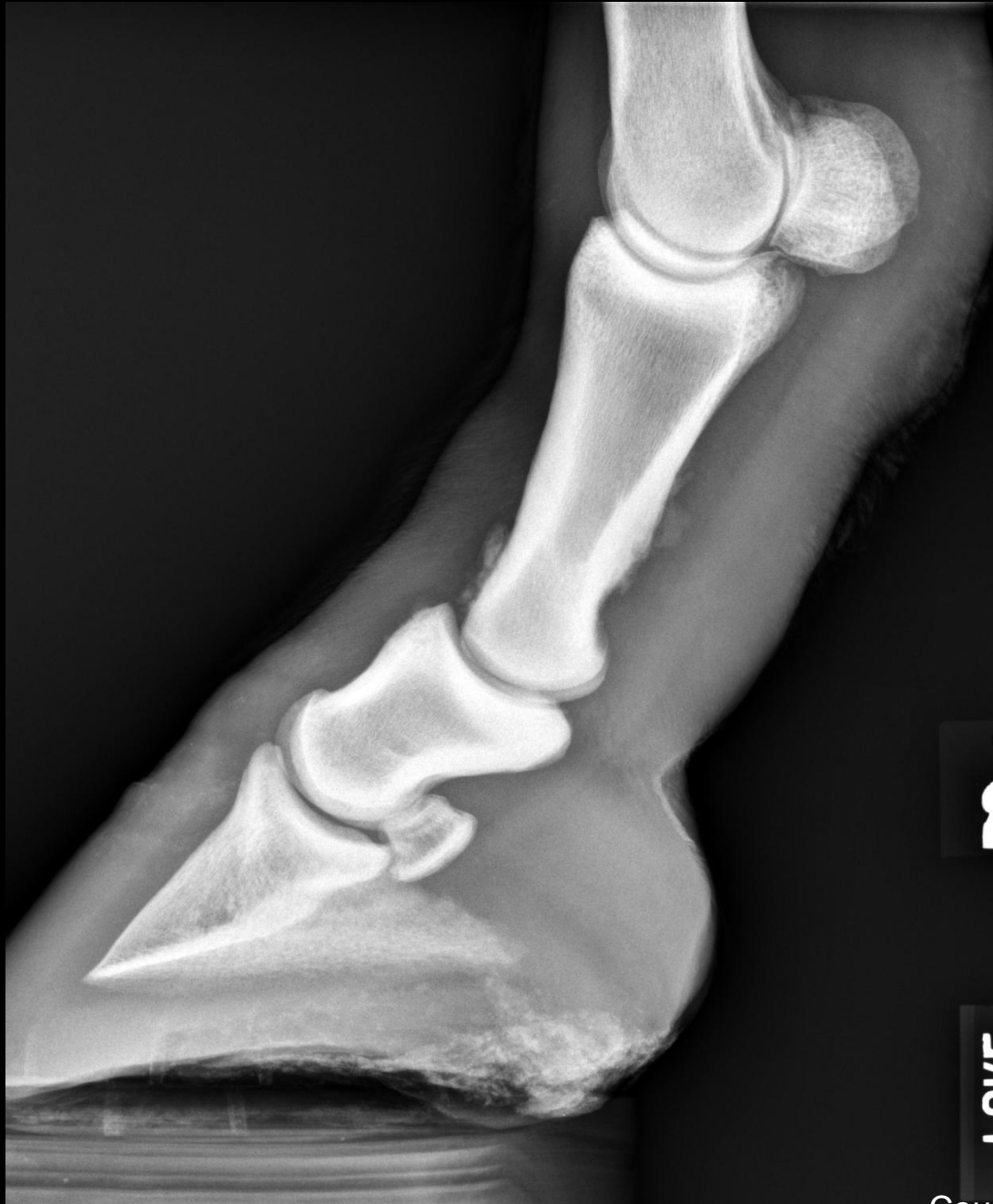

Courtesy of Dr. Myra Barrett



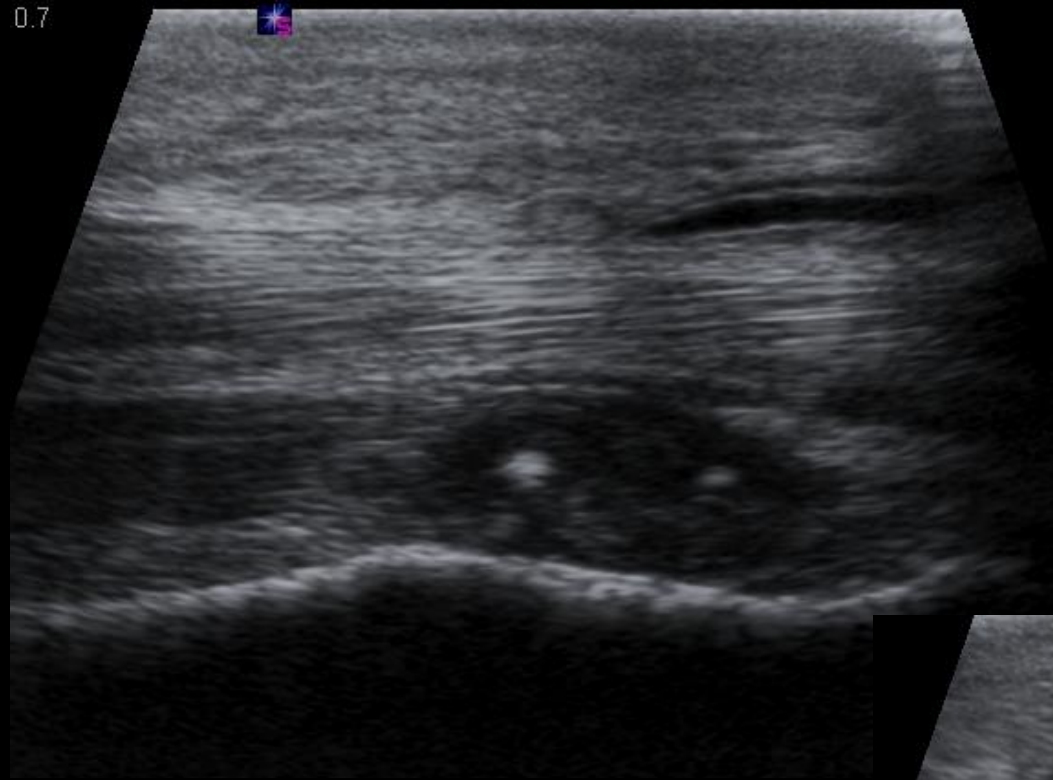
Courtesy of Dr. Myra Barrett

- Fragment removed
- 3 months later, continued lameness (3/5)
- Repeat radiographs & ultrasound

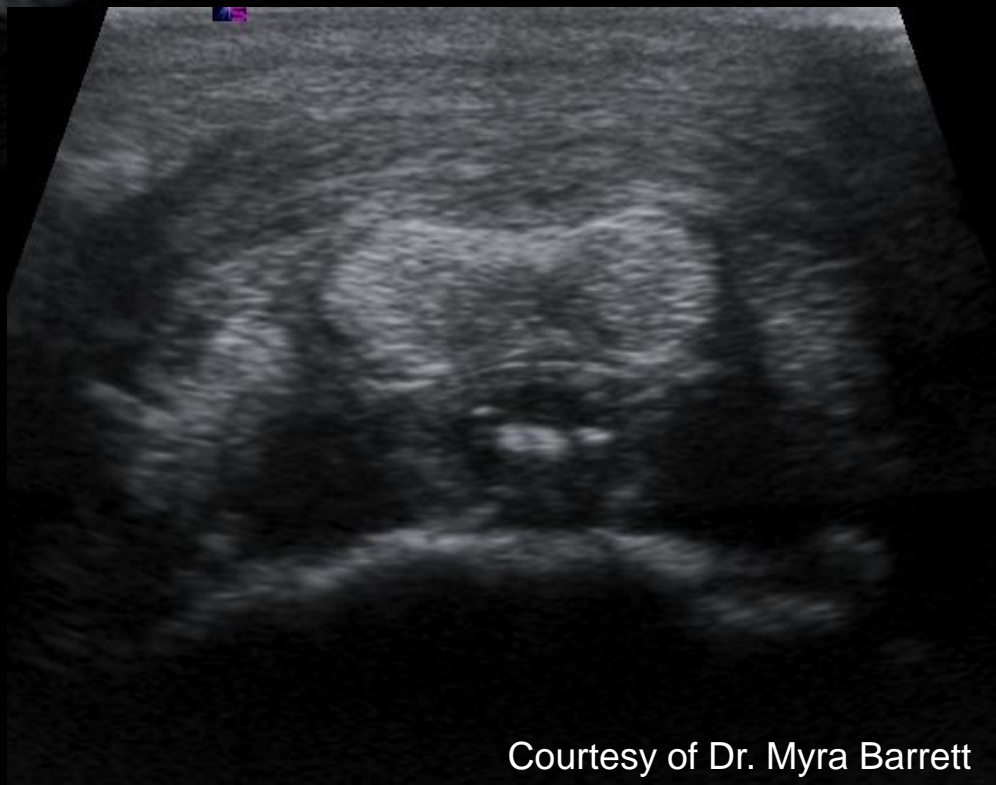


Courtesy of Dr. Myra Barrett

0.7



1



Courtesy of Dr. Myra Barrett

# Case 7

- 5 yr-old QH gelding
- Western performance
- 2-3/5 RF lameness for 3-4 weeks, positive to distal limb flexion
- Significant improvement to PD
- Normal distal limb radiographs

100 ID  
100 RD

V7

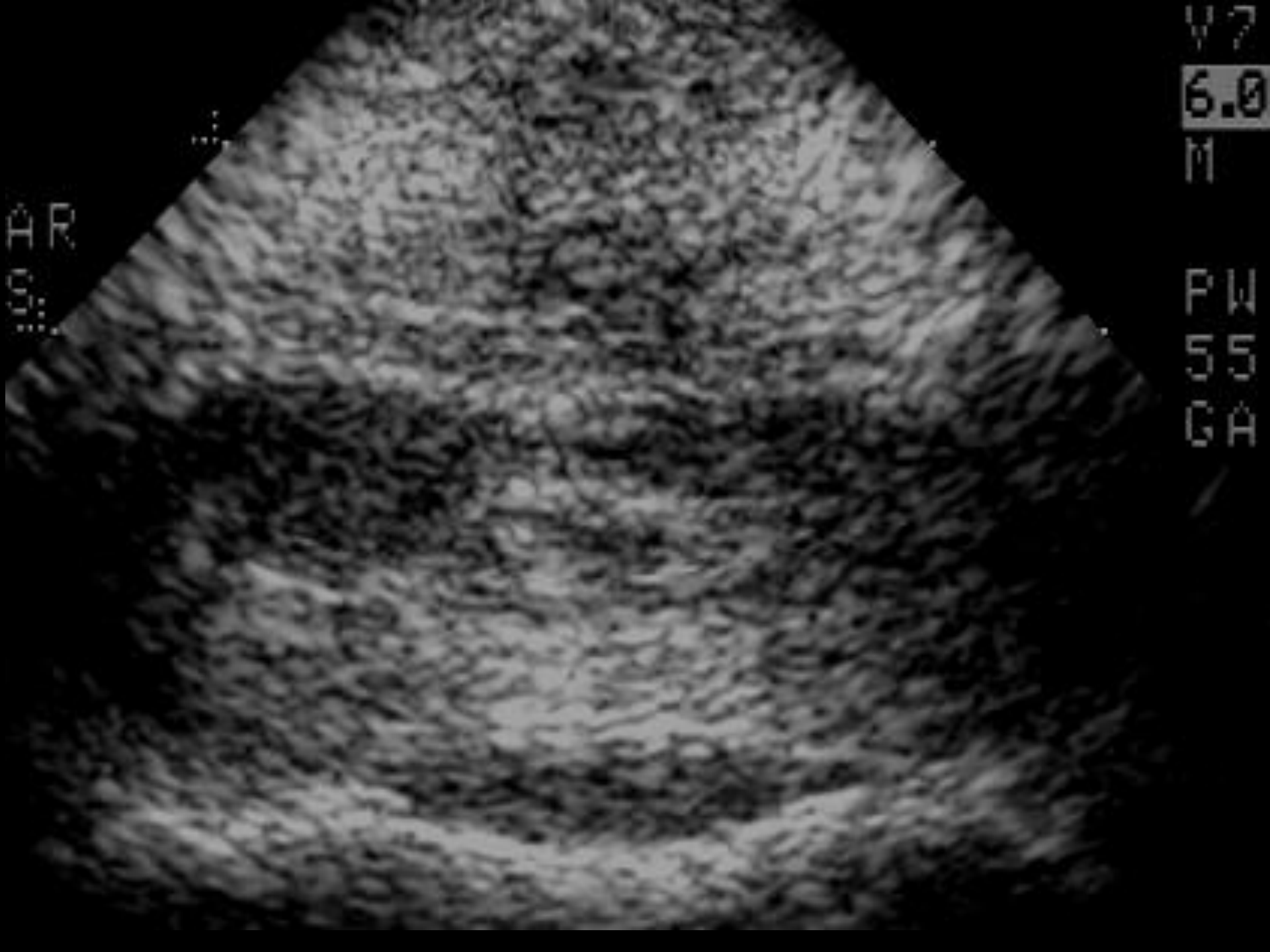
6.0

M

PW

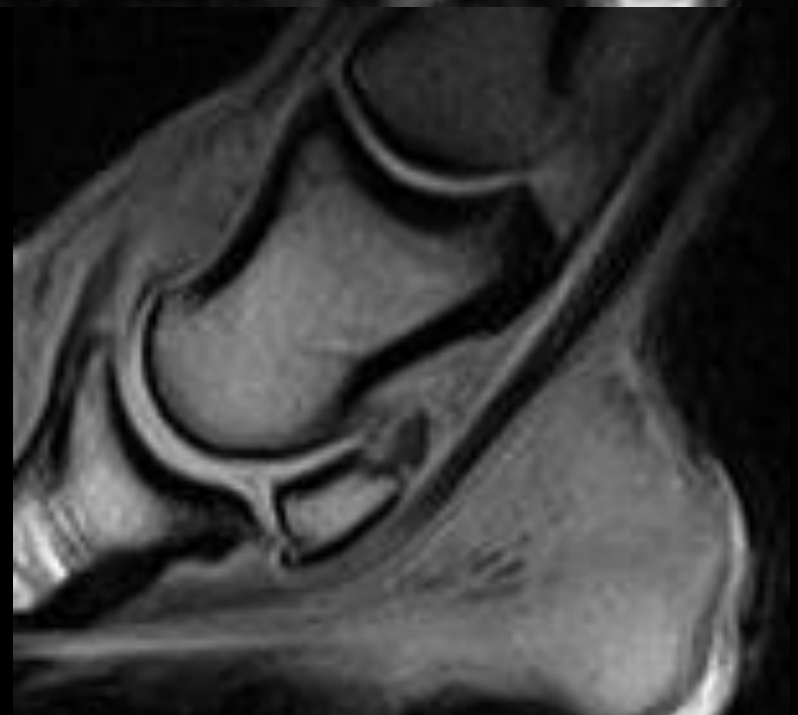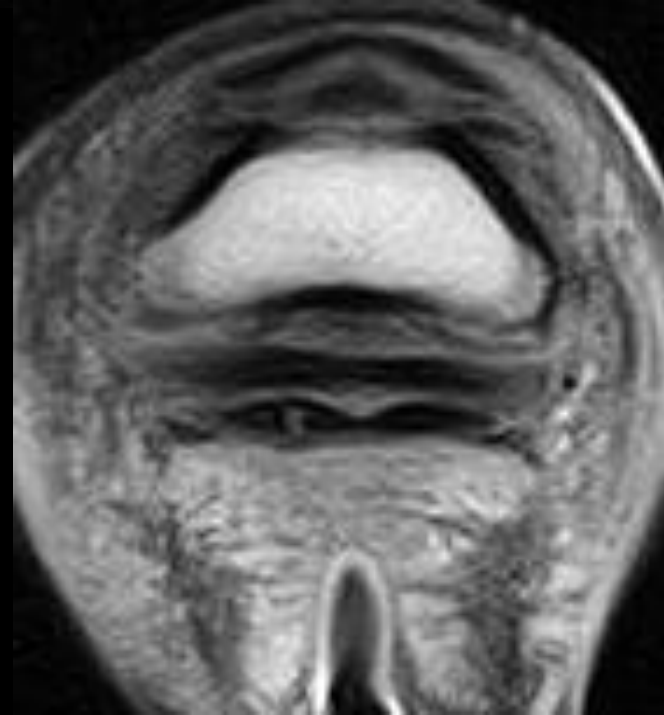
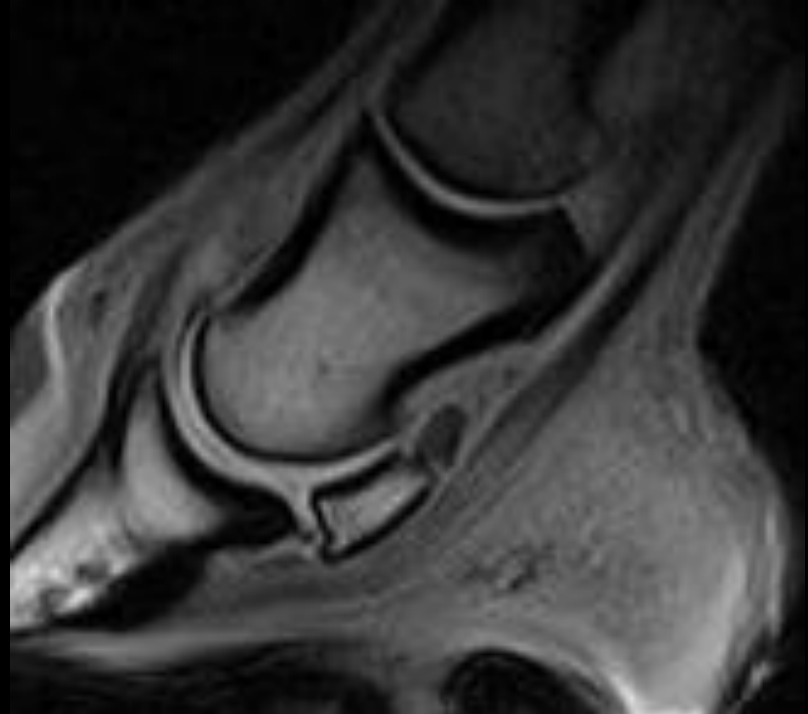
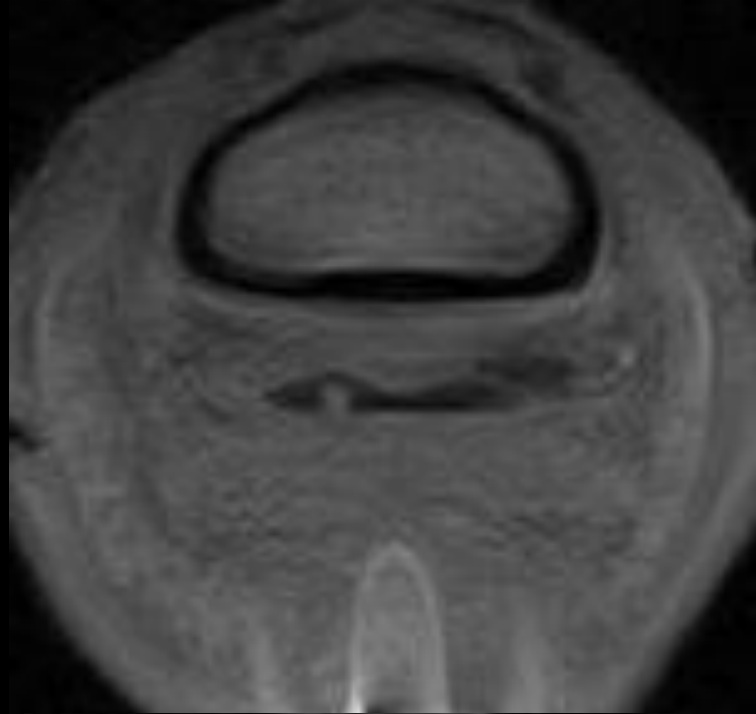
55

GA



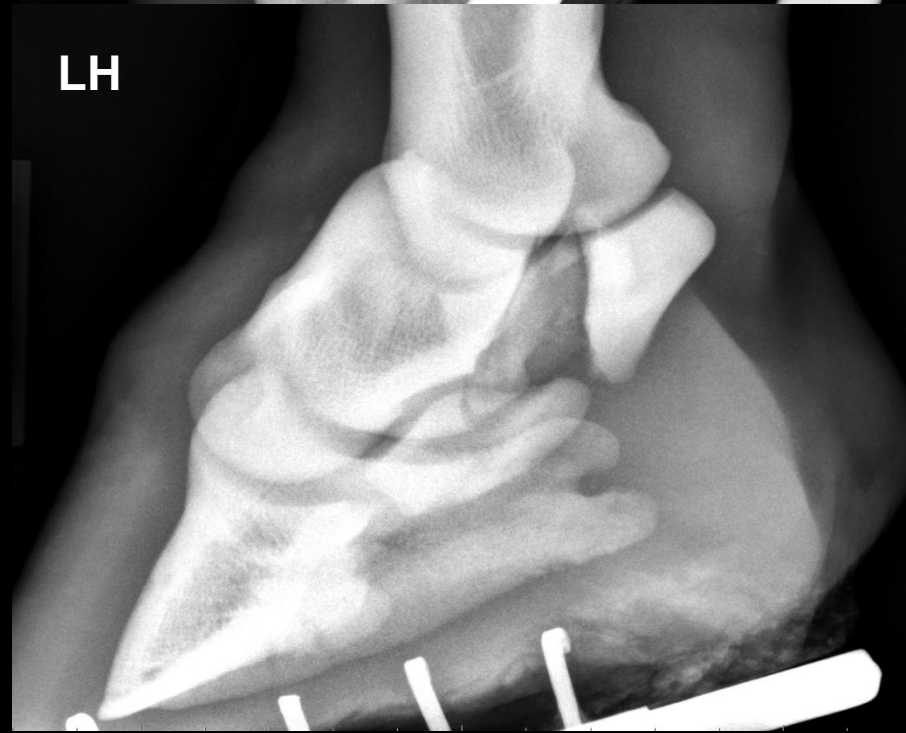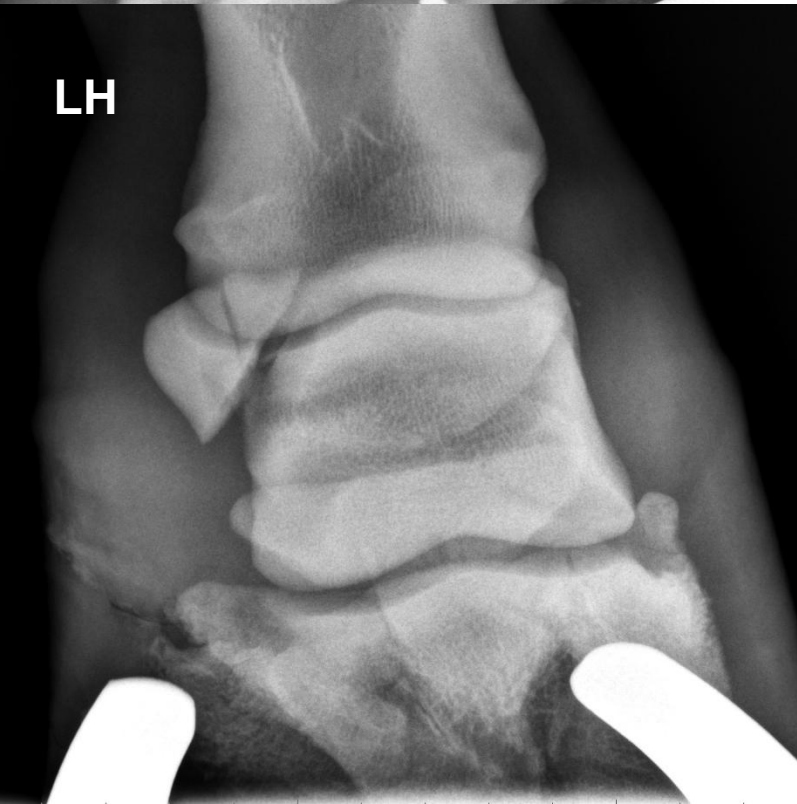
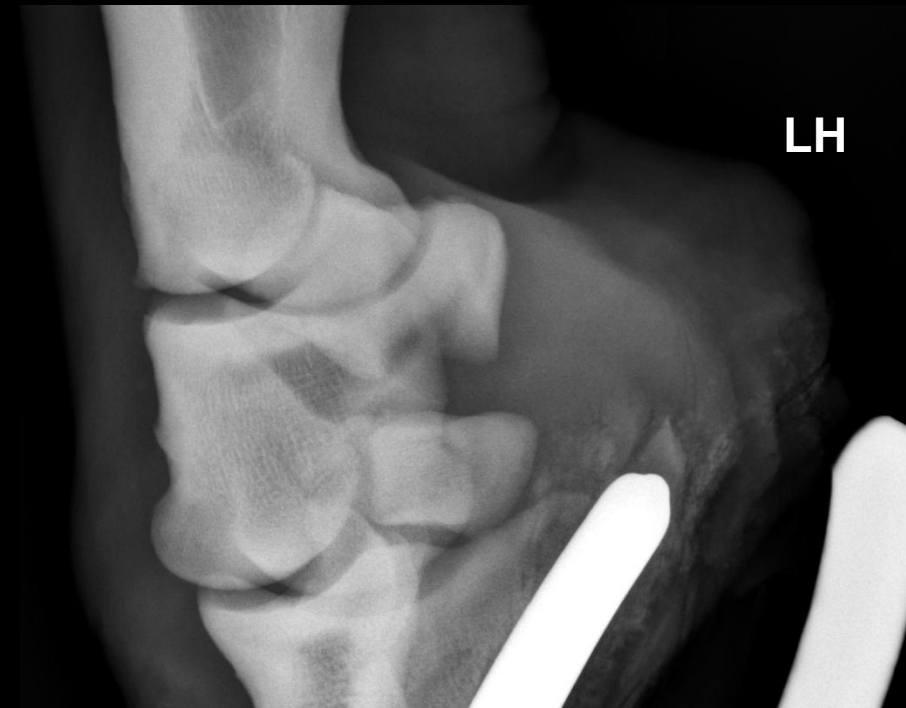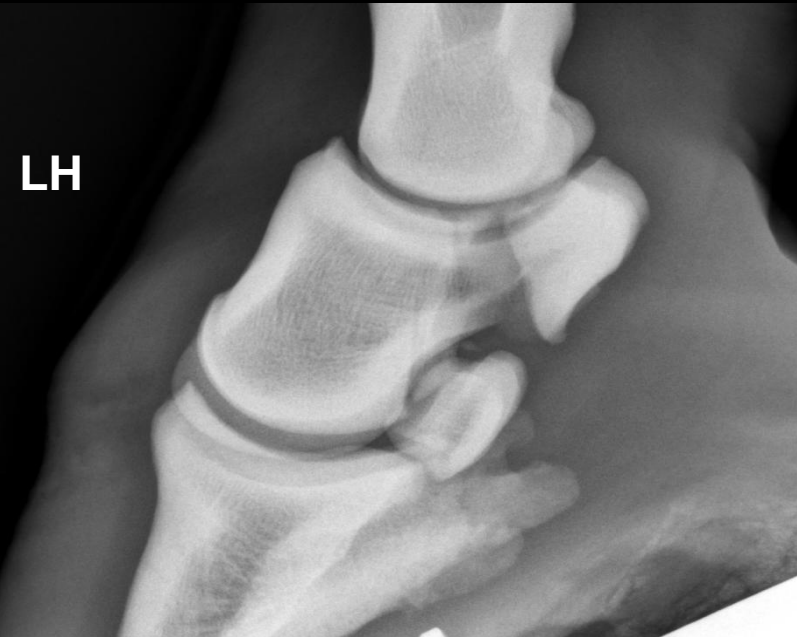# Case 6

- 8 yr-old WB mare
- Dressage
- LF 2-3/5 lameness for 2 months
- Significant improvement to PD
- Normal distal limb radiographs

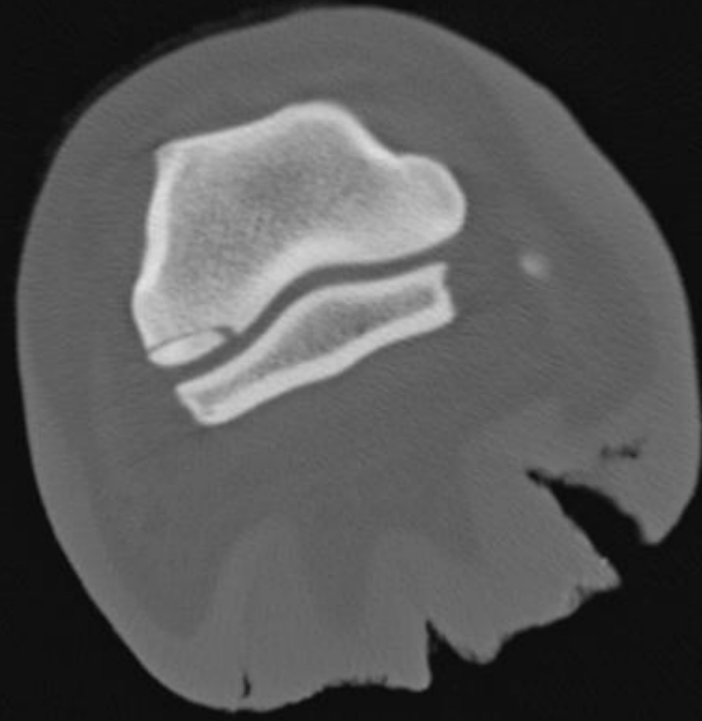
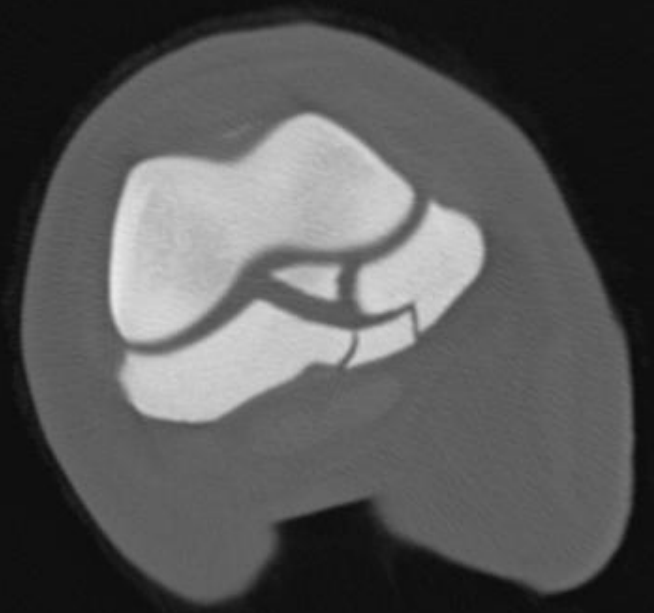
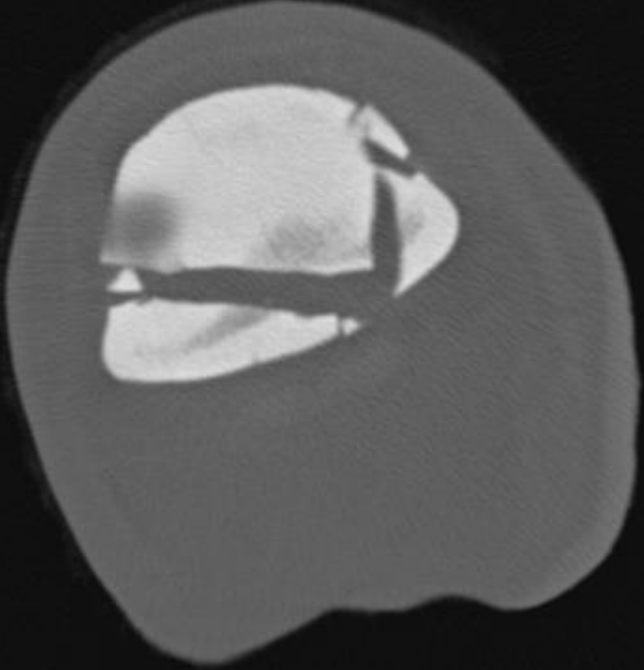


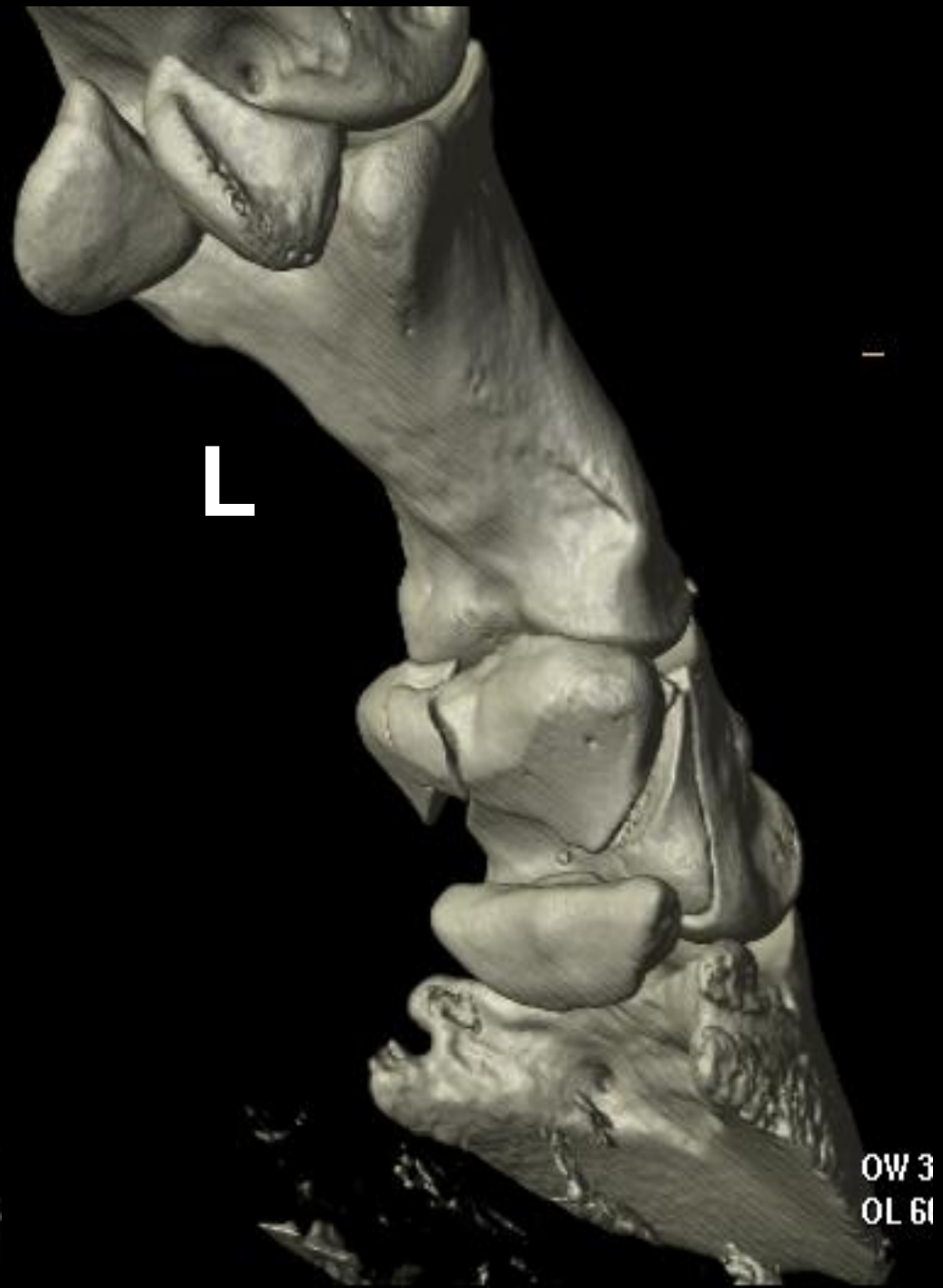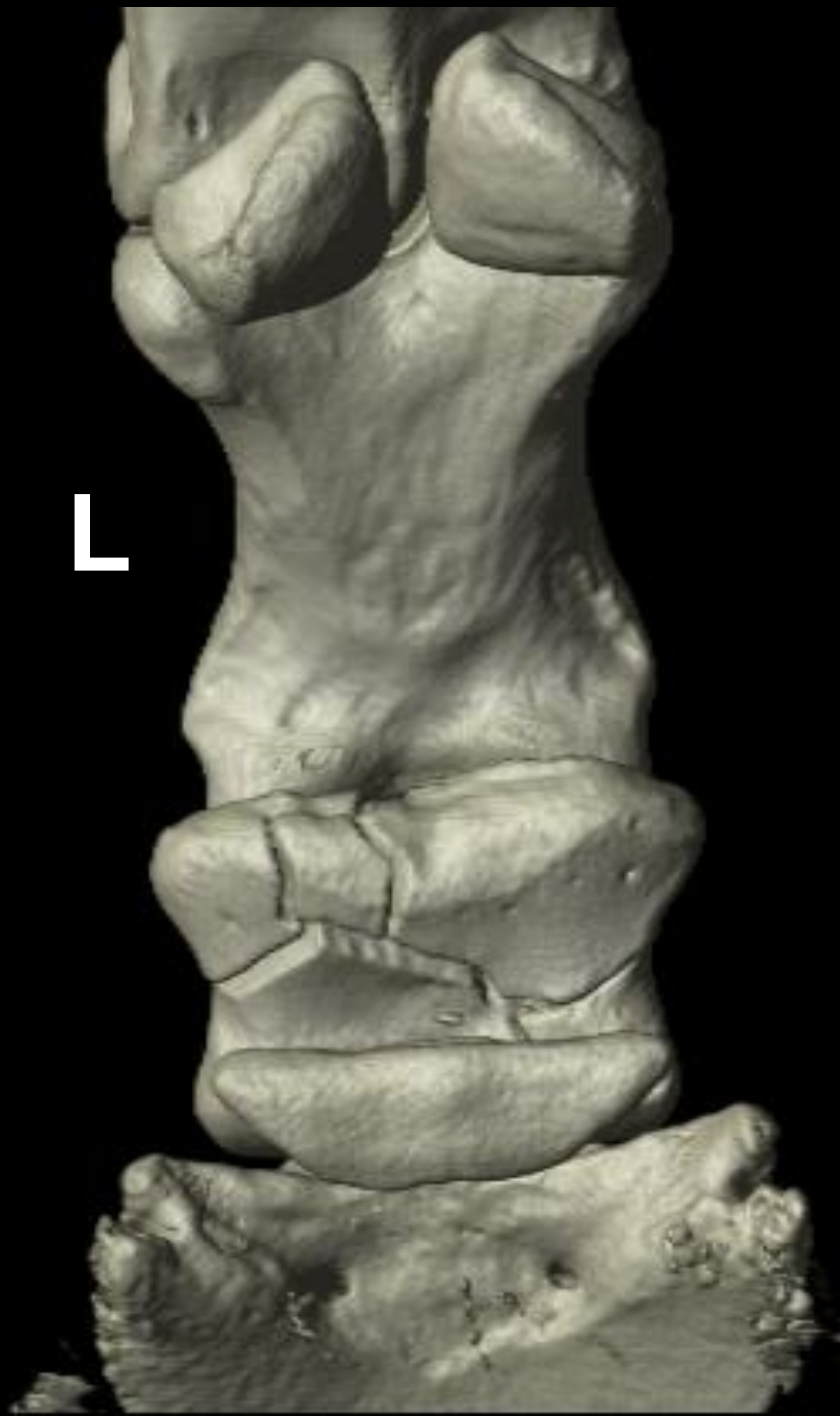# Case 9

- 8 yr-old QH Gelding
- Found in paddock acute non-weight bearing lame LH



MEDIAL ON LEFT





**QUESTIONS**